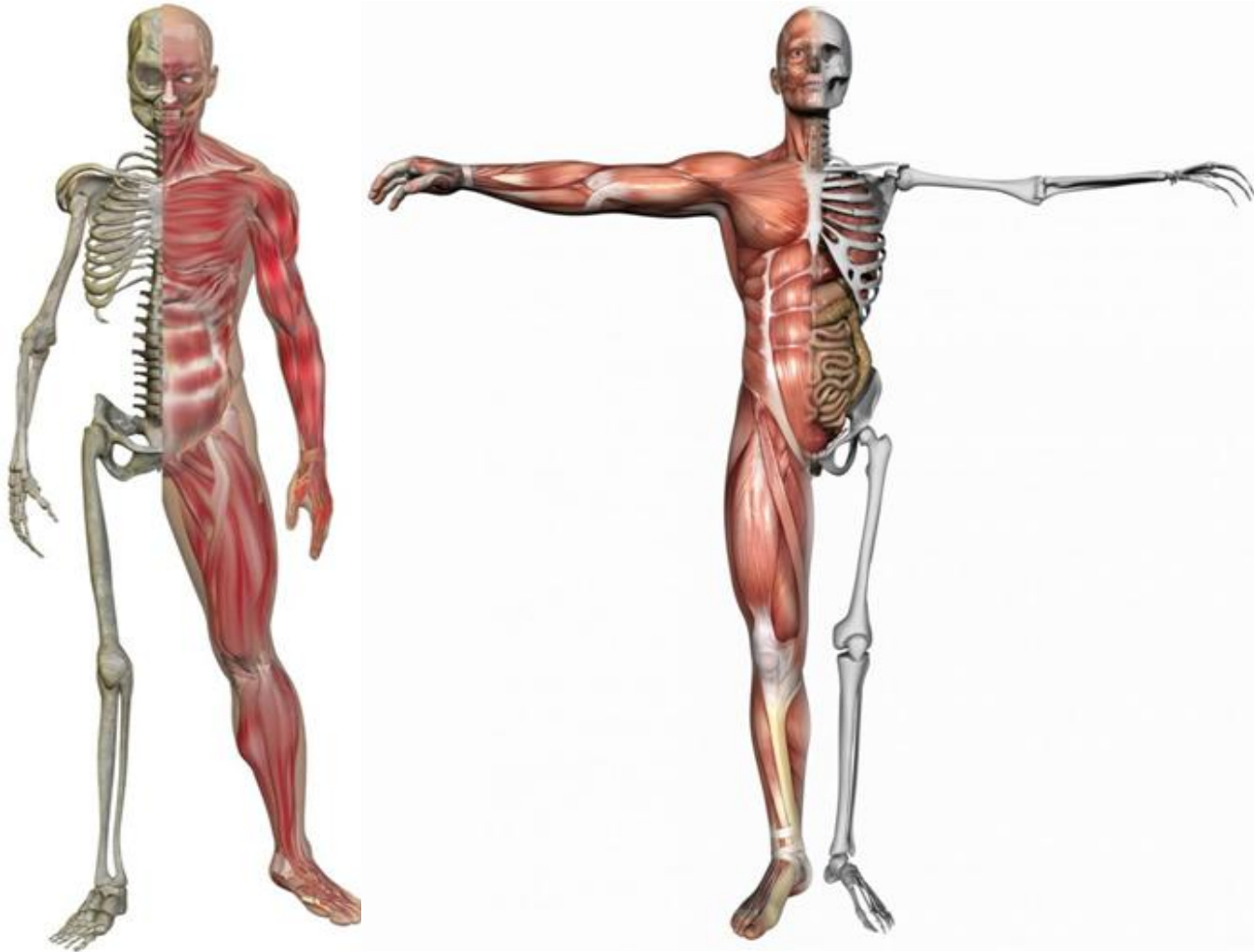


OTOT (MUSCULUS)



AL-MUQSITH

- ▶ Otot (musculus)

jaringan tubuh yg berfungsi mengubah energi kimia menjadi kerja mekanik sebagai respons tubuh terhadap perubahan lingkungan

- ▶ Rangka (skeletal)

bagian tubuh yg tdd tulang, sendi, dan tulang rawan (kartilago) sbg tempat menempelnya otot dan memungkinkan tubuh untuk mempertahankan sikap dan posisi

SIKAP ANATOMI



- Berdiri tegak
- Ekstremitas atas di samping tubuh
- Wajah serta telapak tangan mengarah ke depan
- kedua kaki berdampingan dengan jari-jari kaki mengarah ke depan

SISTEMA MUSCULAR

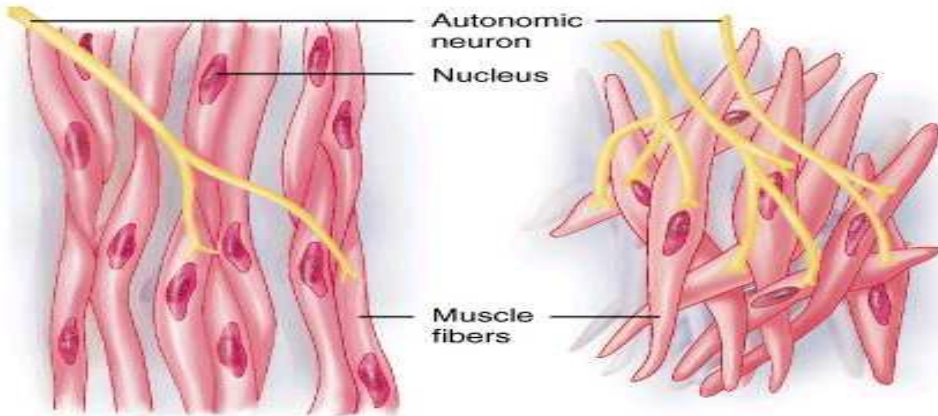
Jaringan otot : 40 – 50 % tubuh

Mempunyai ciri2 :

1. Eksitabilitas (iritabilitas)
 - Bereaksi thdp stimulus, yg pd keadaan normal stimulus berasal dari saraf
2. Kontraktilitas
 - Perubahan bentuk otot krn stimulus, umumnya memendek dan menebal
3. Ekstensibilitas
 - Dapat teregang/memanjang dari panjang normal
4. Elastisitas
 - Kemampuan kembali ke panjang semula bila *stretching* dihilangkan

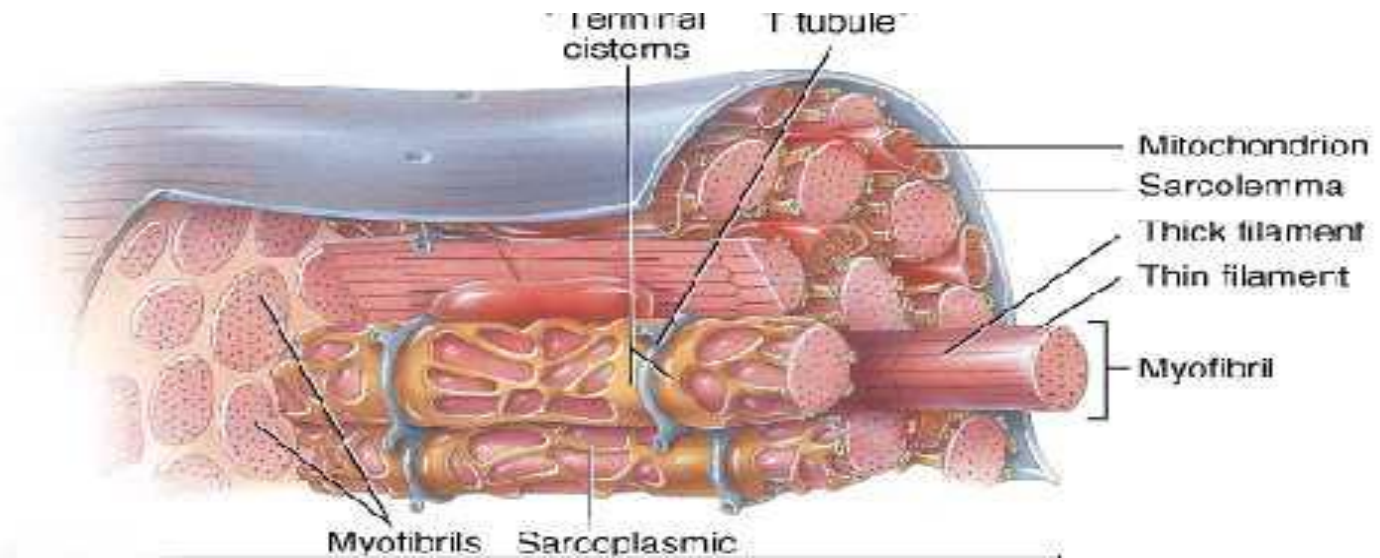
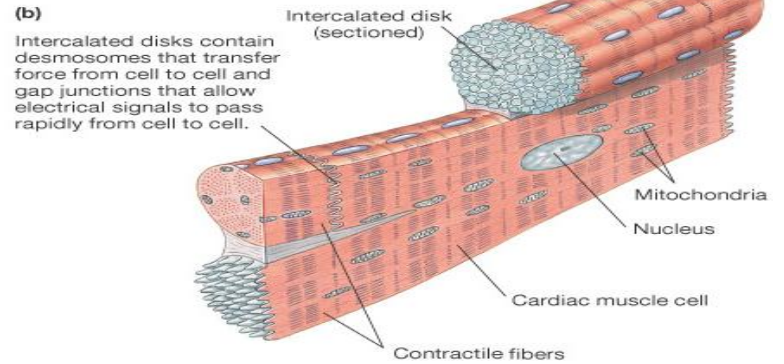
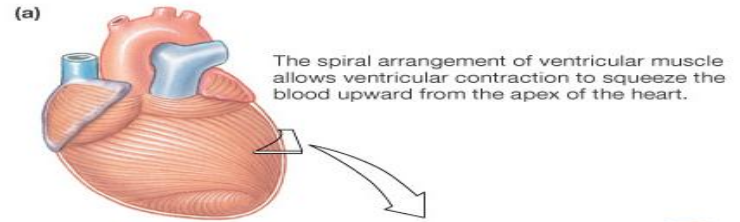
MACAM JARINGAN OTOT :

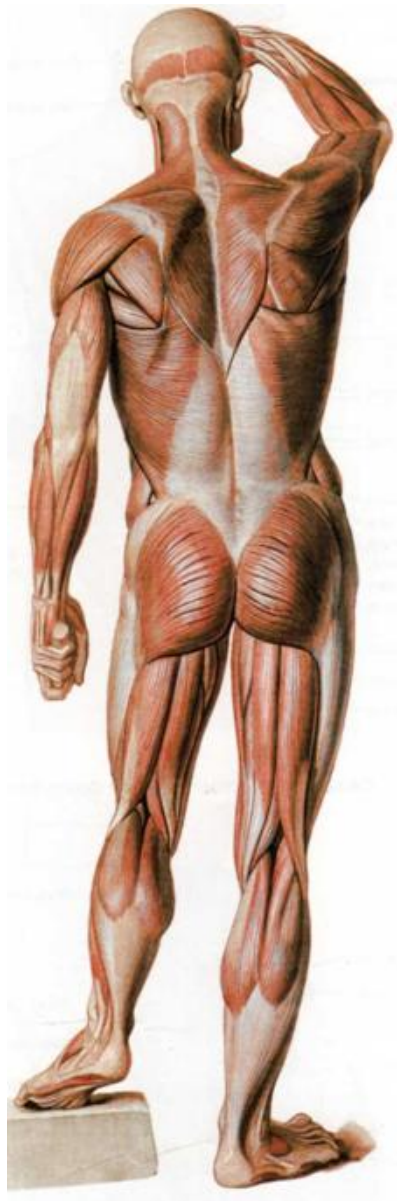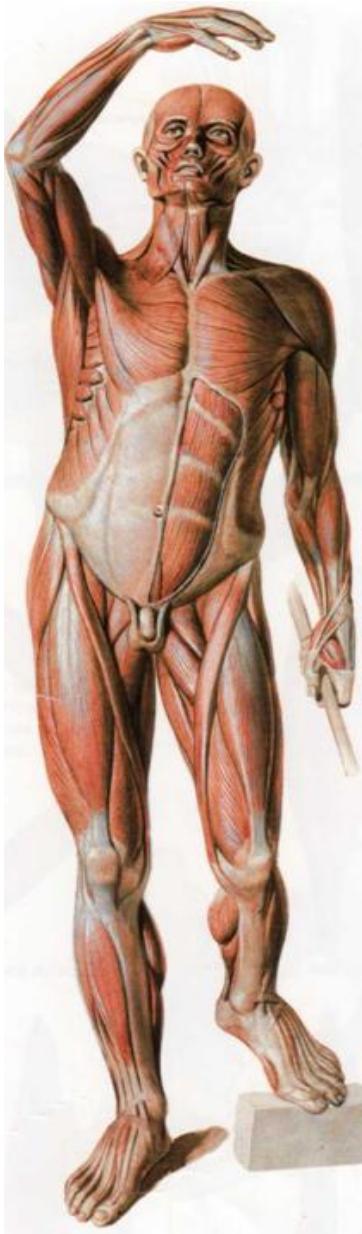1. **CARDIAC**
2. **SMOOTH**
3. **SKELETAL**



(a) Visceral (single-unit) smooth muscle tissue

(b) Multiunit smooth muscle tissue





O
T
O
T

R
A
N
G
K
A

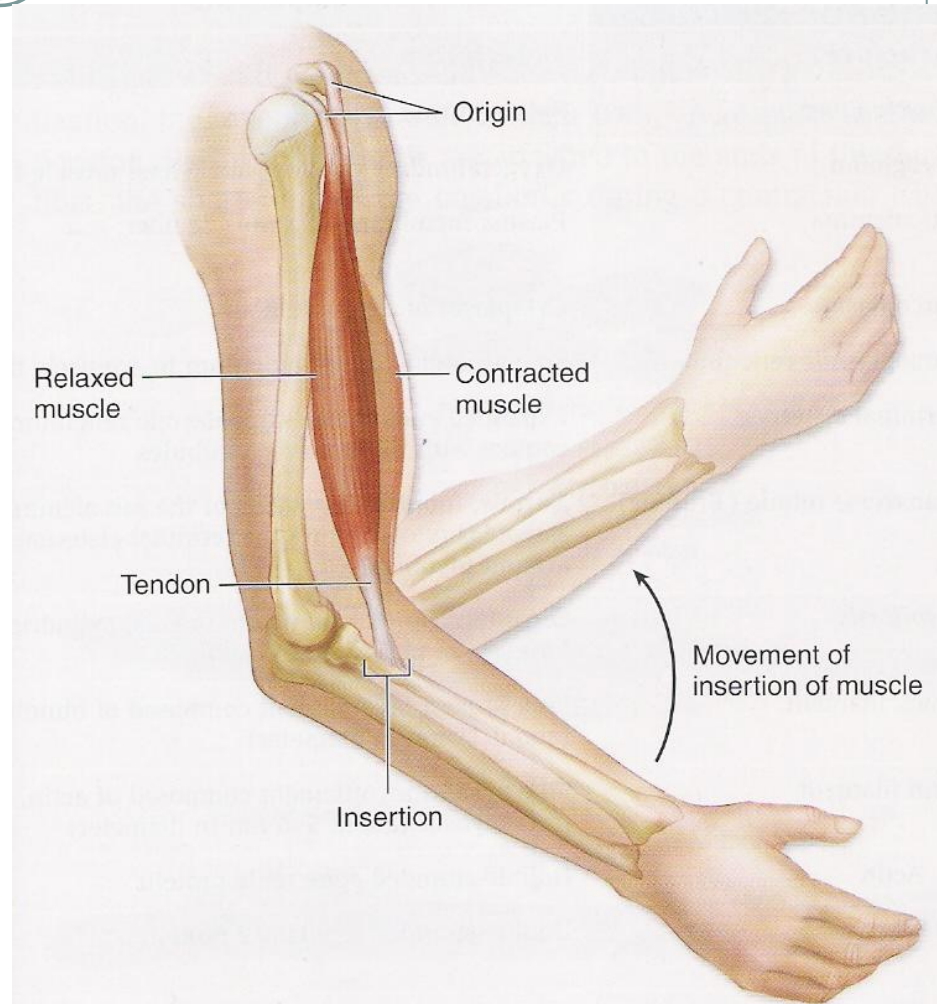
Muscular Skeleton (Otot Rangka)

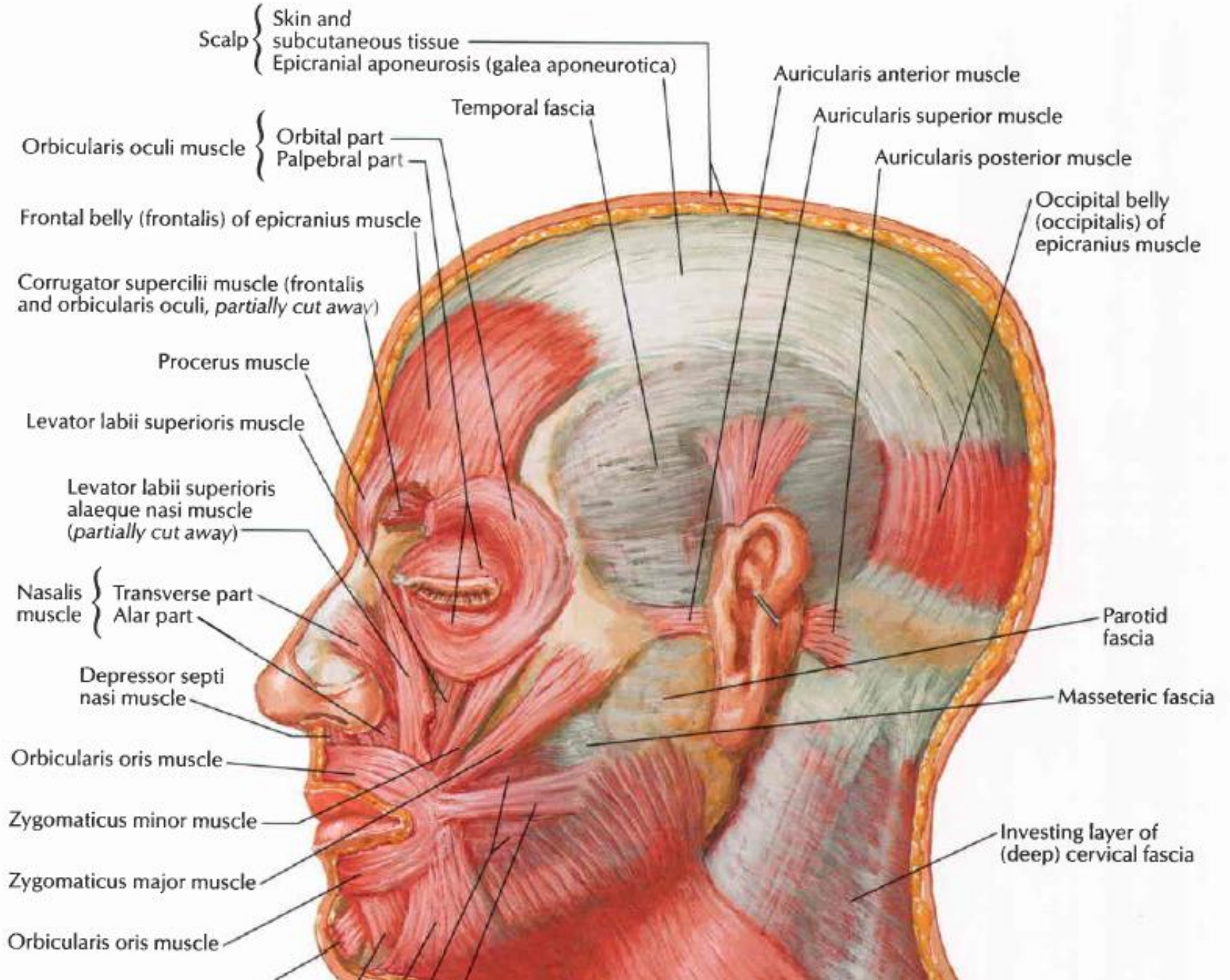


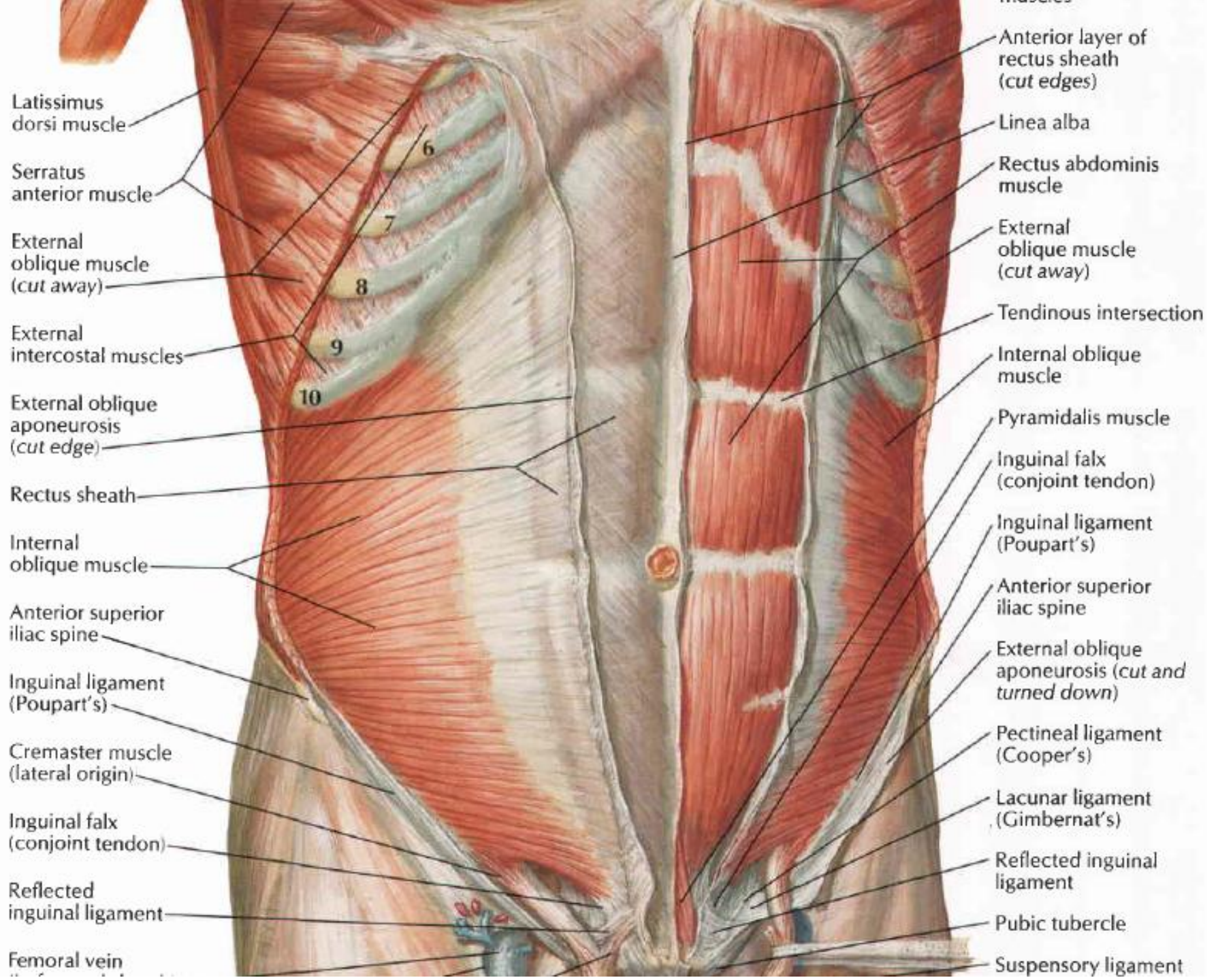
- Otot terdiri atas:
 - Venter (bagian tengah, warna merah)
 - Tendon/aponeurosis (bagian ujung, jar. Ikat warna keputihan)
- Origo: tendon yg melekat pd komponen pasif (punctum fixum) dari pengungkit
- Insertio: tendon yg melekat pd komponen aktif (punctum mobile)
- Fascia: pembungkus otot

PERLEKATAN OTOT

- BAG. TENGAH : >> MUSCLE FIBER → VENTER
- BAG. UJUNG : >> JR IKAT → TENDON / APONEUROSIS → ORIGO / INSERTIO → MELEKAT PADA TULANG, KULIT, OTOT
- ORIGO :
SEDIKIT GERAKAN / MENDEKATI AXIAL SKELETON
- INSERTIO :
GERAKAN LEBIH BANYAK / MENJAUHI AXIAL SKELETON

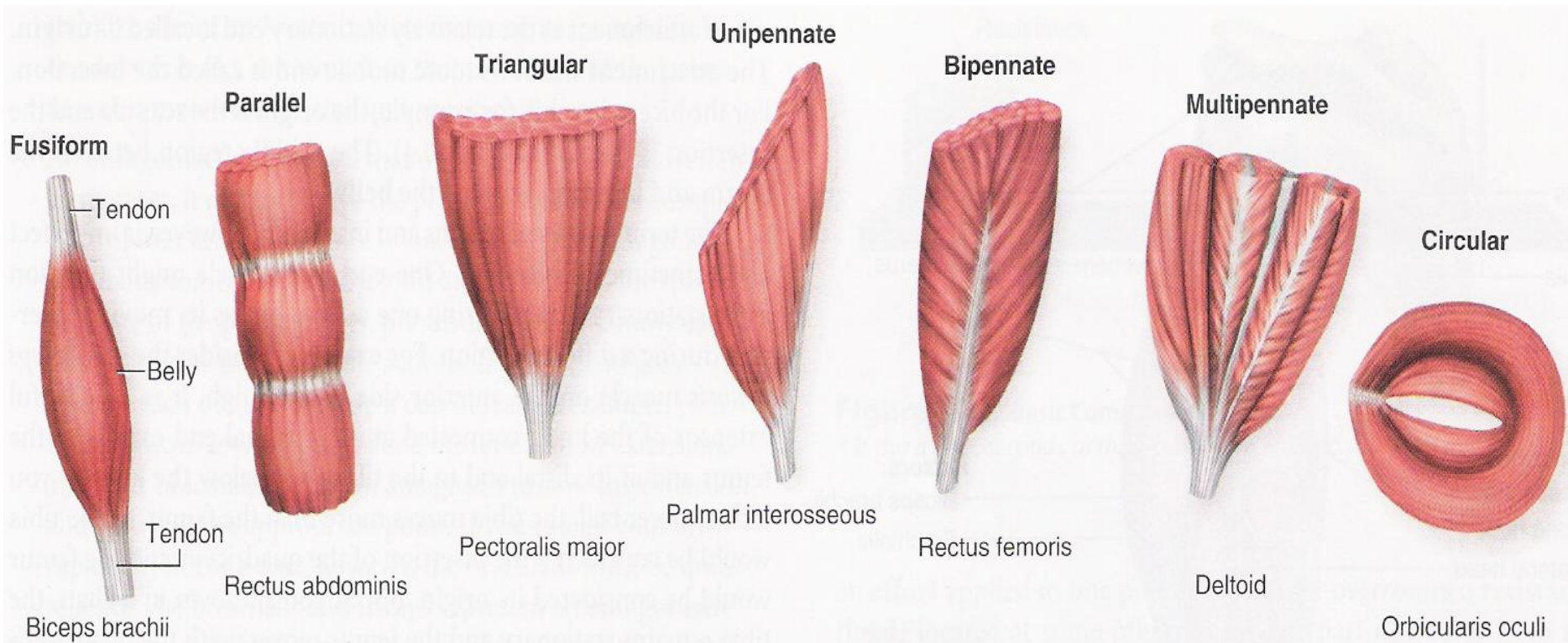






BENTUK OTOT :

1. FUSIFORM
2. PARALEL
3. TRIANGULAR
4. PENNATE :
 - a. UNIPENNATE
 - b. BIPENNATE
 - c. MULTIPENNATE
5. CIRCULAR



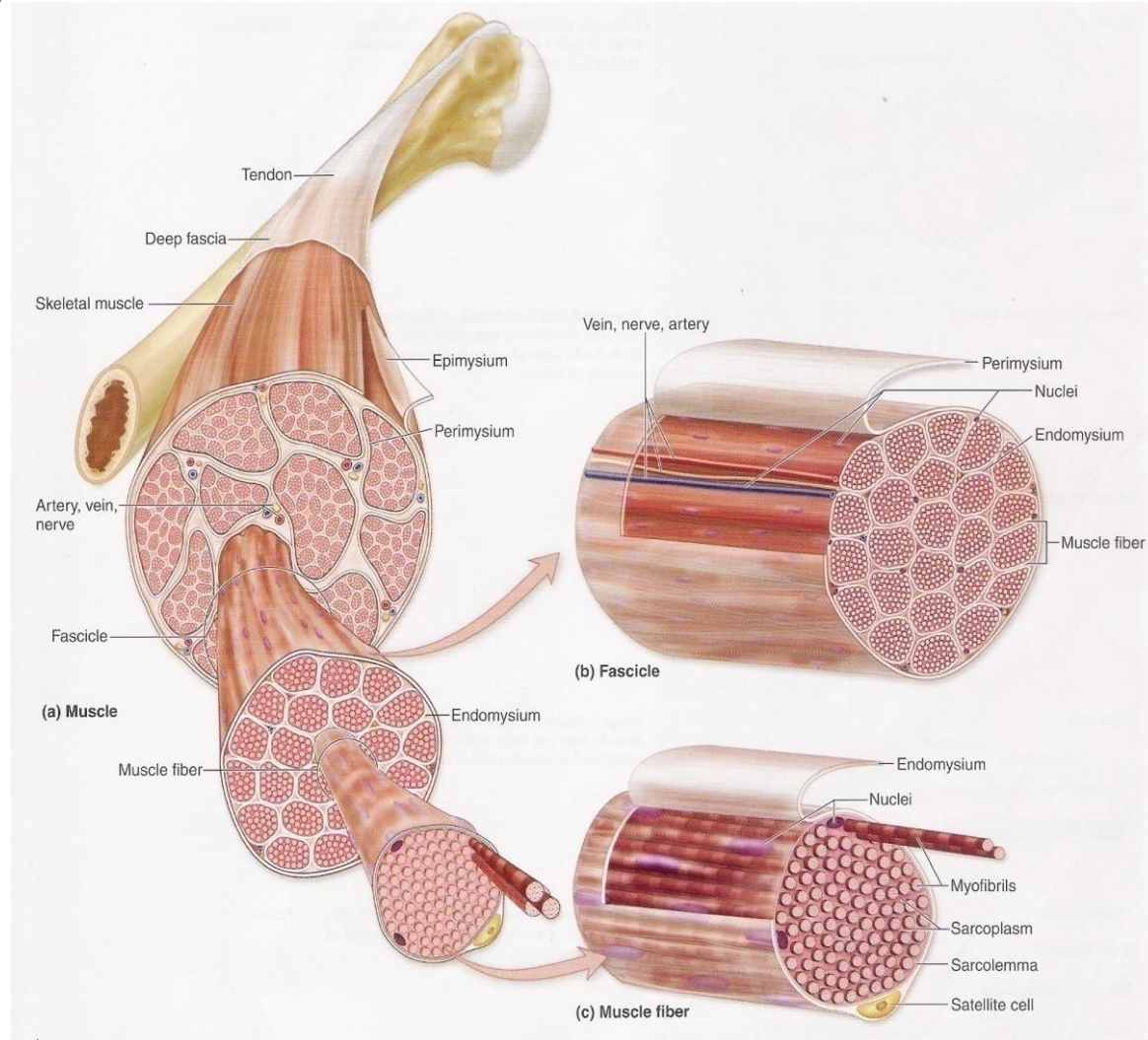
FUNGSI OTOT LURIK



1. Pergerakan tubuh
2. Keseimbangan postur tubuh
3. Pengaturan temperatur/suhu tubuh
4. Mengatur pergerakan makanan dan bahan ekskretorik
5. Pendukung organ lain

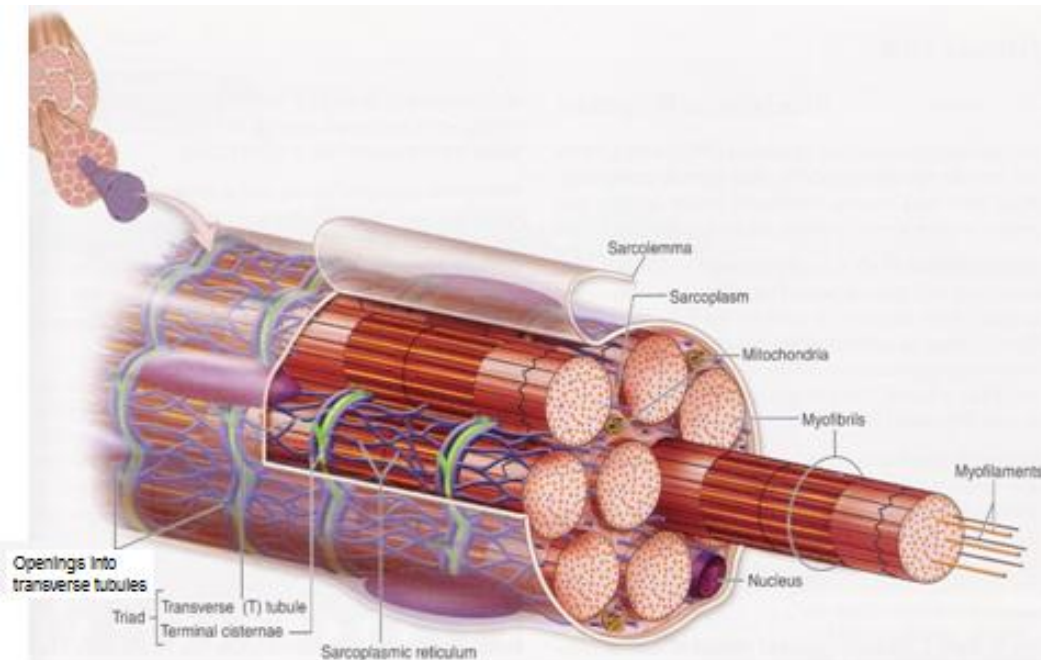
Struktur musculus dari dalam ke luar

- MYOFILAMENT (ACTIN & MYOSIN)
↓
- MYOFIBRIL
↓ sarcoplasma
↓ sarcolemma
- MUSCLE FIBER
↓ endomysium
- FASCICULUS
↓ perimysium
- MUSCULUS (bbrp fasciculus)
→ epimysium
- FASCIA PROFUNDUS/DEEP FASCIA
- FASCIA SUPERFICIALIS (SUBCUTIS)



STRUKTUR MUSCLE FIBER

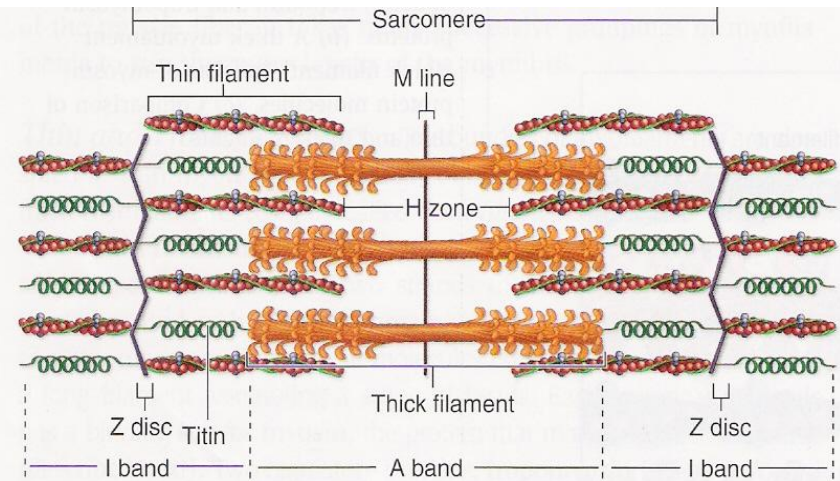
- **Myoglobin** (*oxygen binding pigment*)
 - Depo O₂ untuk kontraksi otot
- **Sarcolemma** (membran plasma muscle fiber)
- **Sarcoplasma** (sitoplasma muscle fiber)
 - Tempat aktivitas metabolisme
 - Lysosom, mitochondria (300), organela
 - Sarcoplasmic reticulum (SR/Smooth endoplasmic reticulum)
 - Depo ion Ca untuk inisiasi kontraksi otot
 - Terminal cisterna
 - Perluasan ujung SR, melekat dengan T-Tubule, tempat pelepasan Ca ion utk memacu kontraksi otot
 - Transverse tubule (T-tubule)
 - Tonjolan tubular dari sarcolemma ke sarcoplasma melekat dengan terminal cisterna, mengelilingi myofibril
 - Menghantarkan muscle impuls dari sarcolemma keseluruhan muscle fiber




STRUKTUR MYOFIBRIL

Disusun 2 macam myofilament :

- **Thick filament**, disusun oleh *double strand* (ujungnya membentuk bulbus) protein **myosin** (\varnothing 11 nm), yg mengadakan ikatan dng actin utk kontraksi
- **Thin filament**, disusun oleh protein actin, troponin & tropomyosin (\varnothing 5-6 nm)
 - **Actin** : *double stranded contractile protein*, mengadakan ikatan dengan myosin utk kontraksi
 - **Tropomyosin** : *double stranded regulatory protein*, menutup sisi aktif dari actin \rightarrow mencegah ikatan dng myosin saat relaksasi
 - **Troponin** : *regulatory protein*, melekatkan tropomyosin pada actin. Ikatan dng Ca \rightarrow ikatan tropomyosin dng actin lepas \rightarrow kontraksi
 - **Titin** : suatu elastic protein, membantu ke posisi awal myofilament stlh kontraksi



(b)



(c)

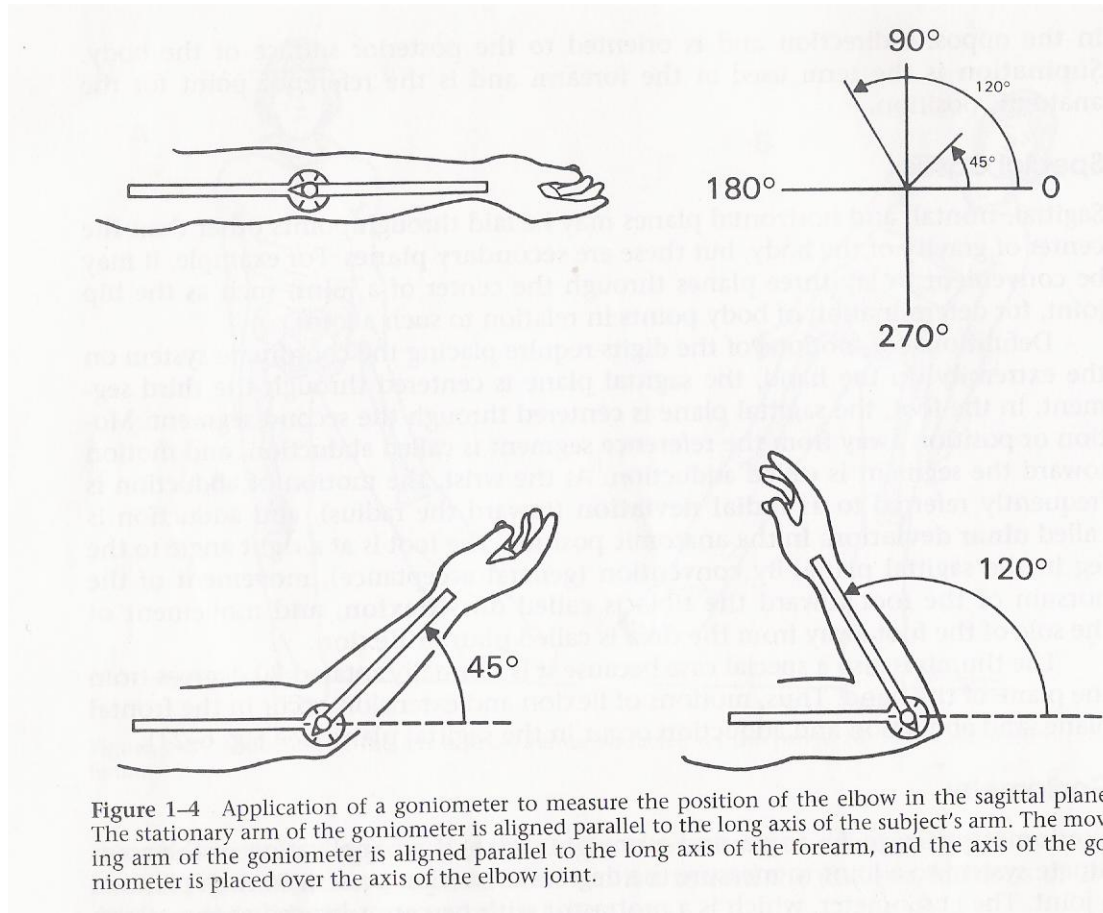
RANGE OF MOTION

JARAK SUATU GERAKAN (FLEXIBILITAS),

TERGANTUNG:

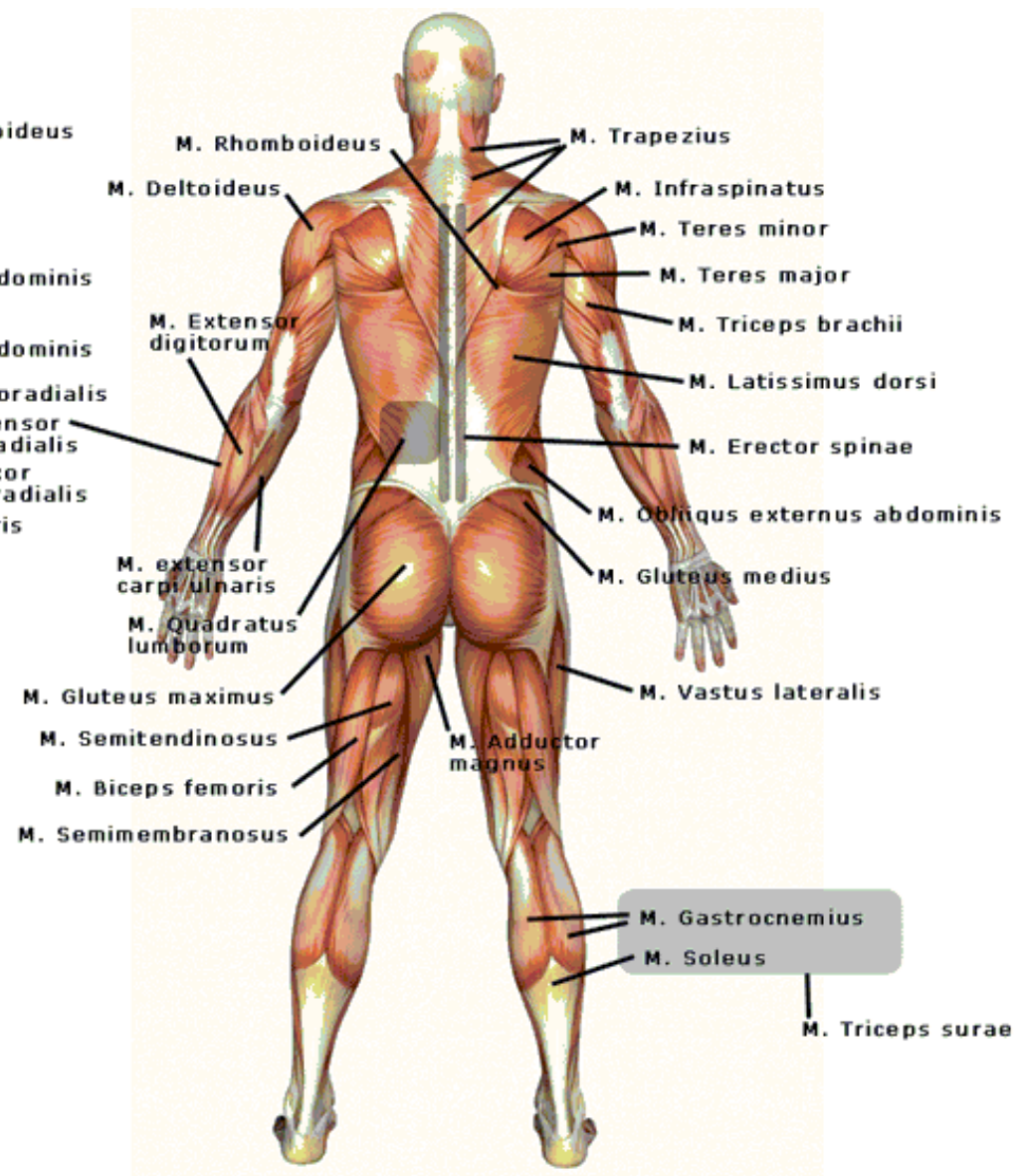
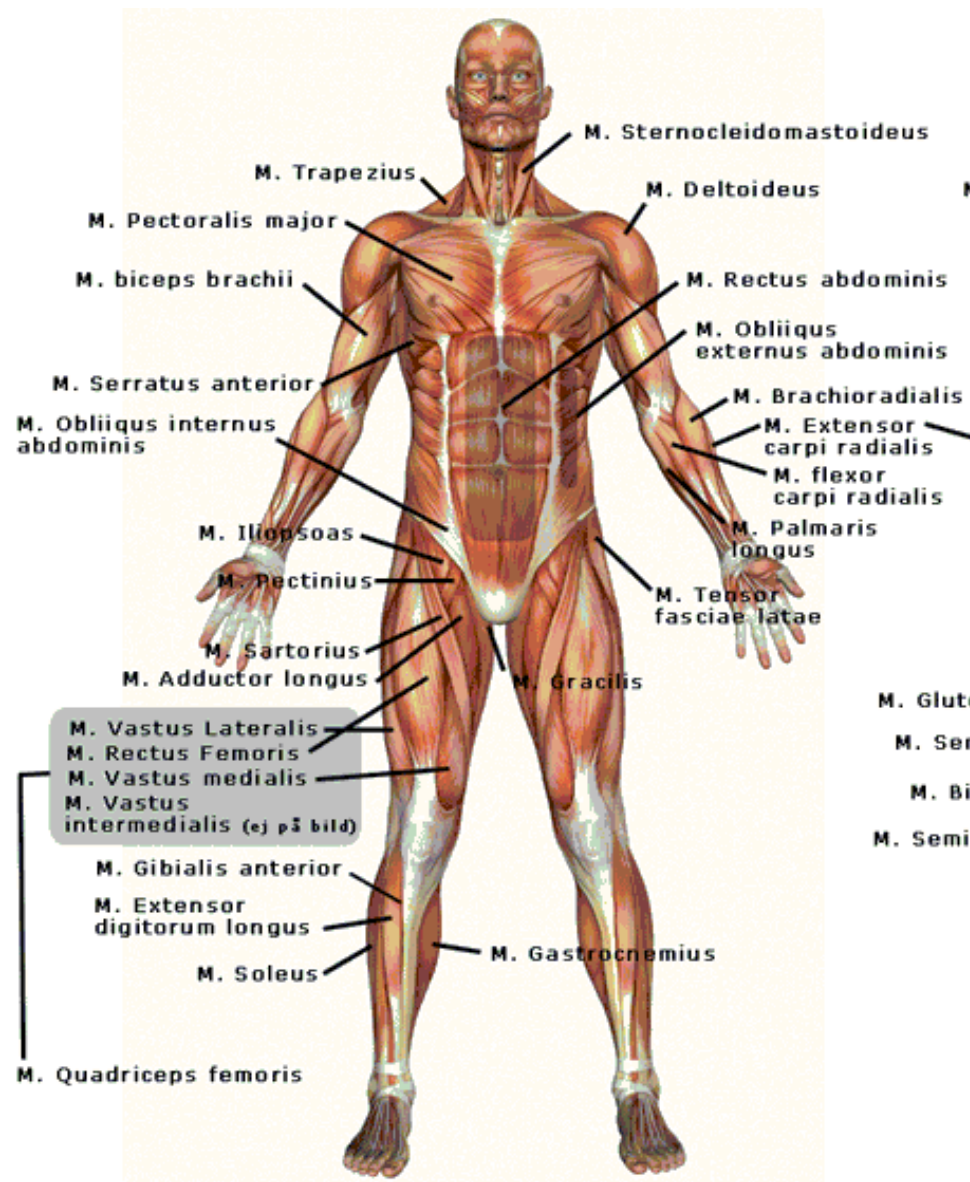
1. JARINGAN SEKITAR SENDI
2. ELASTISITAS OTOT, TENDON,
LIGAMENT SEKITAR SENDI
3. STRUKTUR TULANG → SENDI

RANGE OF MOTION



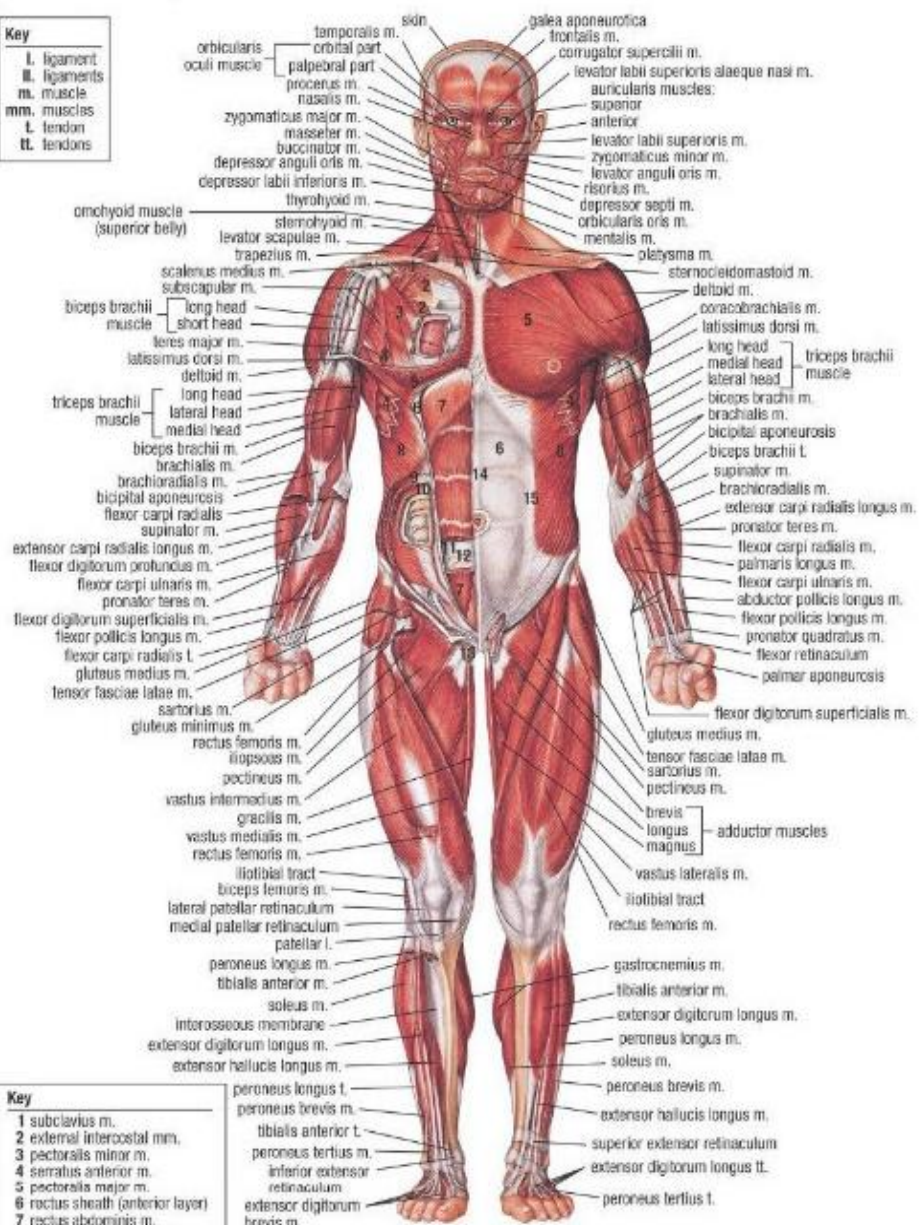
Summary Ranges of Joint Motion

SHOULDER	flexion 0° to 180° (150° to 180°) extension 0° hyperextension 0° to 45° (40° to 60°) abduction 0° to 180° (150° to 180°) internal rotation 0° to 90° (70° to 90°) external rotation 0° to 90° (80° to 90°)	THUMB	MCP flexion 0° to 45° (40° to 90°) MCP abduction and adduction (NEGLIGIBLE) IP flexion 0° to 90° (80° to 90°)
ELBOW	flexion 0° to 145° (120° to 160°) extension 0°	HIP	flexion 0° to 120° (110° to 125°) hyperextension 0° to 10° (0° to 30°) abduction 0° to 45° (40° to 55°) adduction 0° (30° to 40° across midline) external rotation 0° to 45° (40° to 50°) internal rotation 0° to 35° (30° to 45°)
FOREARM	supination from midposition 0° to 90° (80° to 90°) pronation from midposition 0° to 80° (70° to 80°)	KNEE	flexion 0° to 120° (120° to 160°) extension 0°
WRIST	neutral when the midline between flexion and extension is 0° and when forearm and third metacarpal are in line flexion 0° to 90° (75° to 90°) extension 0° to 70° (65° to 70°) radial abduction 0° to 20° (15° to 25°) ulnar abduction 0° to 30° (25° to 40°)	ANKLE	neutral with foot at a right angle to the leg and knee flexed plantar flexion 0° to 45° (40° to 50°) dorsiflexion 0° to 15° (10° to 20°) inversion and eversion (see Chapter 10).
FINGERS	MCP flexion 0° to 90° (85° to 100°) MCP hyperextension 0° to 20° (0° to 45°) MCP abduction 0° to 20° MCP adduction 0° PIP flexion 0° to 120° (90° to 120°) DIP flexion 0° to 90° (80° to 90°) IP extension 0°	TOES	MTP flexion 0° to 40° (30° to 45°) MTP hyperextension 0° to 80° (50° to 90°) MTP abduction (present) IP flexion 0° to 60° (50° to 80°) IP extension 0°



MUSCULAR SYSTEM (ANTERIOR VIEW)

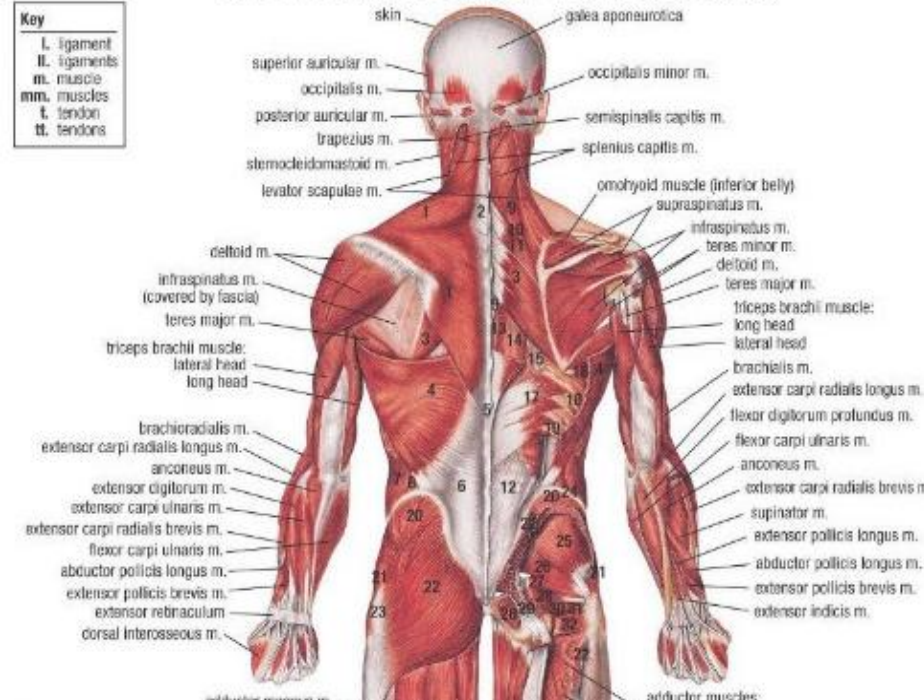
Key
 I. ligament
 II. ligaments
 m. muscle
 mm. muscles
 t. tendon
 tt. tendons



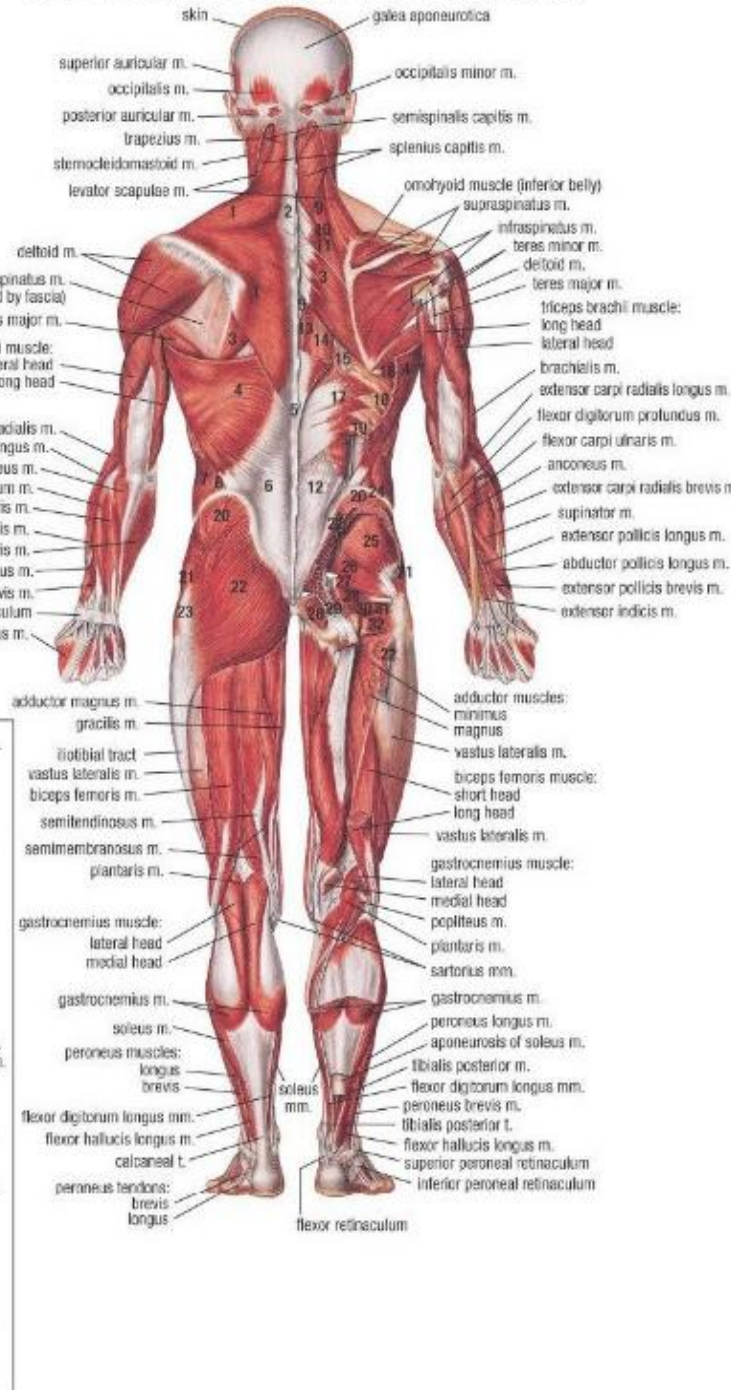
Key
 1 subclavius m.
 2 external intercostal mm.
 3 pectoralis minor m.
 4 serratus anterior m.
 5 pectoralis major m.
 6 rectus sheath (anterior layer)
 7 rectus abdominis m.
 8 external abdominal oblique m.
 9 internal abdominal oblique m.
 10 transversus abdominis m.
 11 rectus sheath (posterior layer)
 12 arcuate line
 13 cremaster m.
 14 linea alba
 15 aponeurosis of external abdominal oblique m.

MUSCULAR SYSTEM (POSTERIOR VIEW)

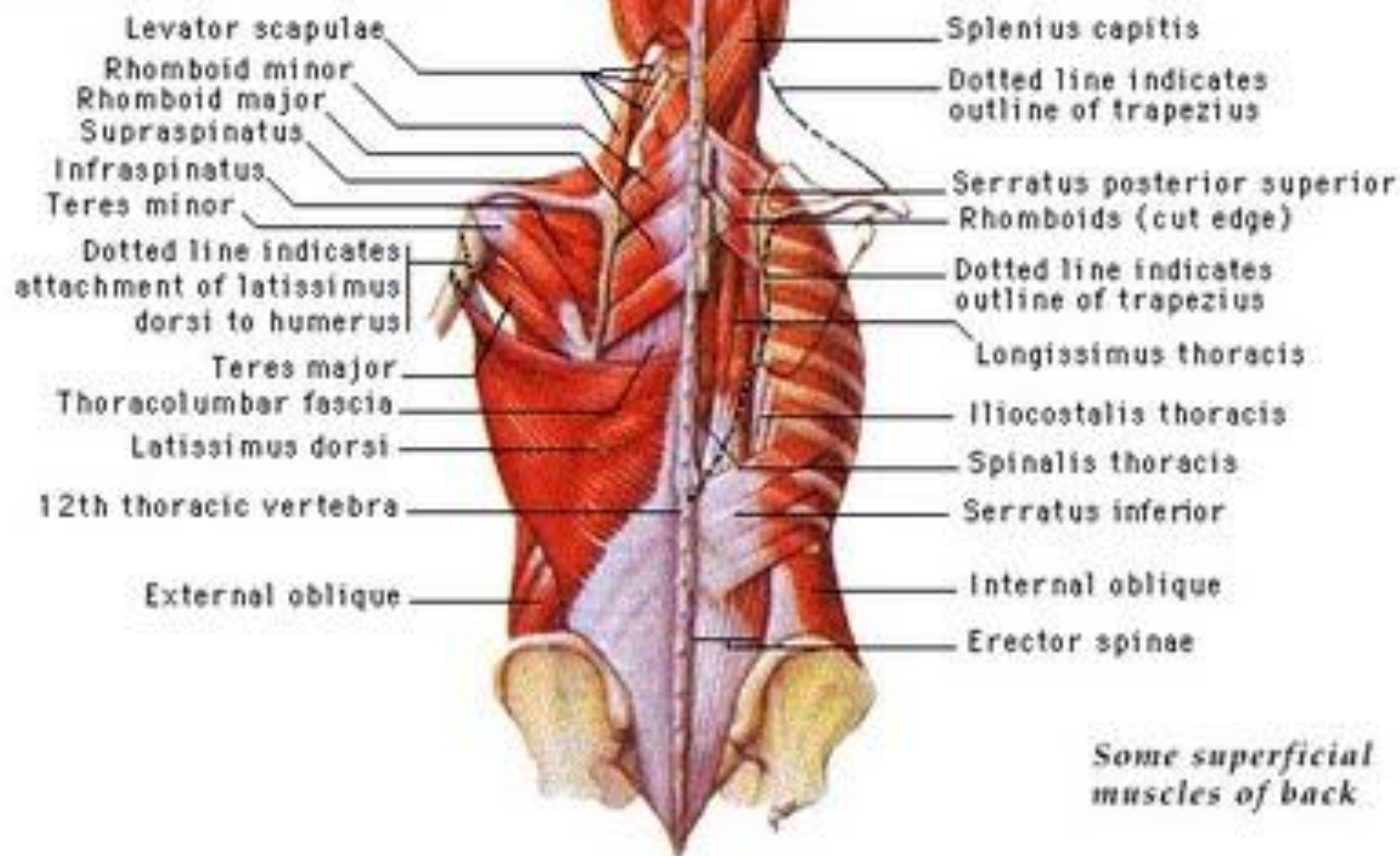
Key
 I. ligament
 II. ligaments
 m. muscle
 mm. muscles
 t. tendon
 tt. tendons



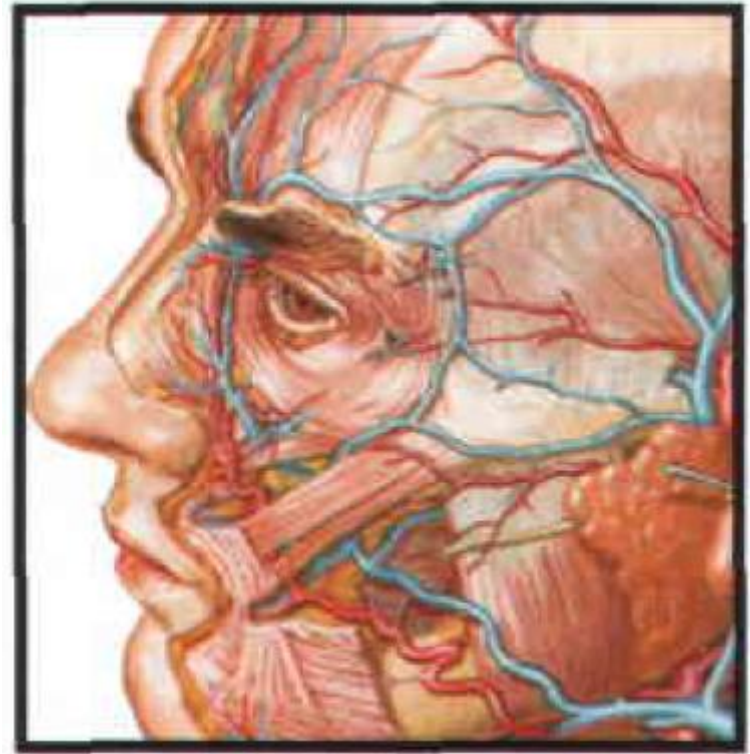
Key
 1 trapezius m.
 2 spine of C7
 3 rhomboid major m.
 4 latissimus dorsi m.
 5 spine of T12
 6 thoracolumbar fascia
 7 external abdominal oblique m.
 8 internal abdominal oblique m.
 9 splenius cervicis m.
 10 serratus posterior superior m.
 11 rhomboid minor m.
 12 erector spinae mm.
 13 spinalis thoracis m.
 14 longissimus thoracis m.
 15 iliocostalis lumborum m.
 16 serratus anterior m.
 17 serratus posterior inferior m.
 18 external intercostal m.
 19 12th rib
 20 gluteus medius m.
 21 tensor fasciae latae m.
 22 gluteus maximus m.
 23 greater trochanter
 24 iliac crest
 25 gluteus minimus m.
 26 piriformis m.
 27 superior gemellus m.
 28 obturator internus m.
 29 sacrotuberous l.
 30 inferior gemellus m.
 31 obturator externus m.
 32 quadratus femoris m.



MUSCULAR SYSTEM



Caput et Collum



Otot-otot Pengunyah

1.	M. temporalis	Nn. Temporales profundi (N. Mandibularis [V/3])
2.	M. masseter	N. Mandibularis [V/3]
3.	M. pterygoideus medialis	N. pterygoideus medialis (N. Mandibularis [V/3])
4.	M. pterygoideus lateralis	N. pterygoideus lateralis (N. Mandibularis [V/3])

Dahi, parietal, pelipis

1.	M. occipitofrontalis	N. Facialis [VII]
2.	M. temporoparietalis	
3.	M. Auricularis anterior	
4.	M. Auricularis superior	
5.	M. Auricularis posterior	

Kelopak Mata

1.	M. Orbicularis oculi	N. Facialis [VII]
2.	M. Depressor supercilii	
3.	M. Currogator supercilii	
4.	M. procerus	

Hidung

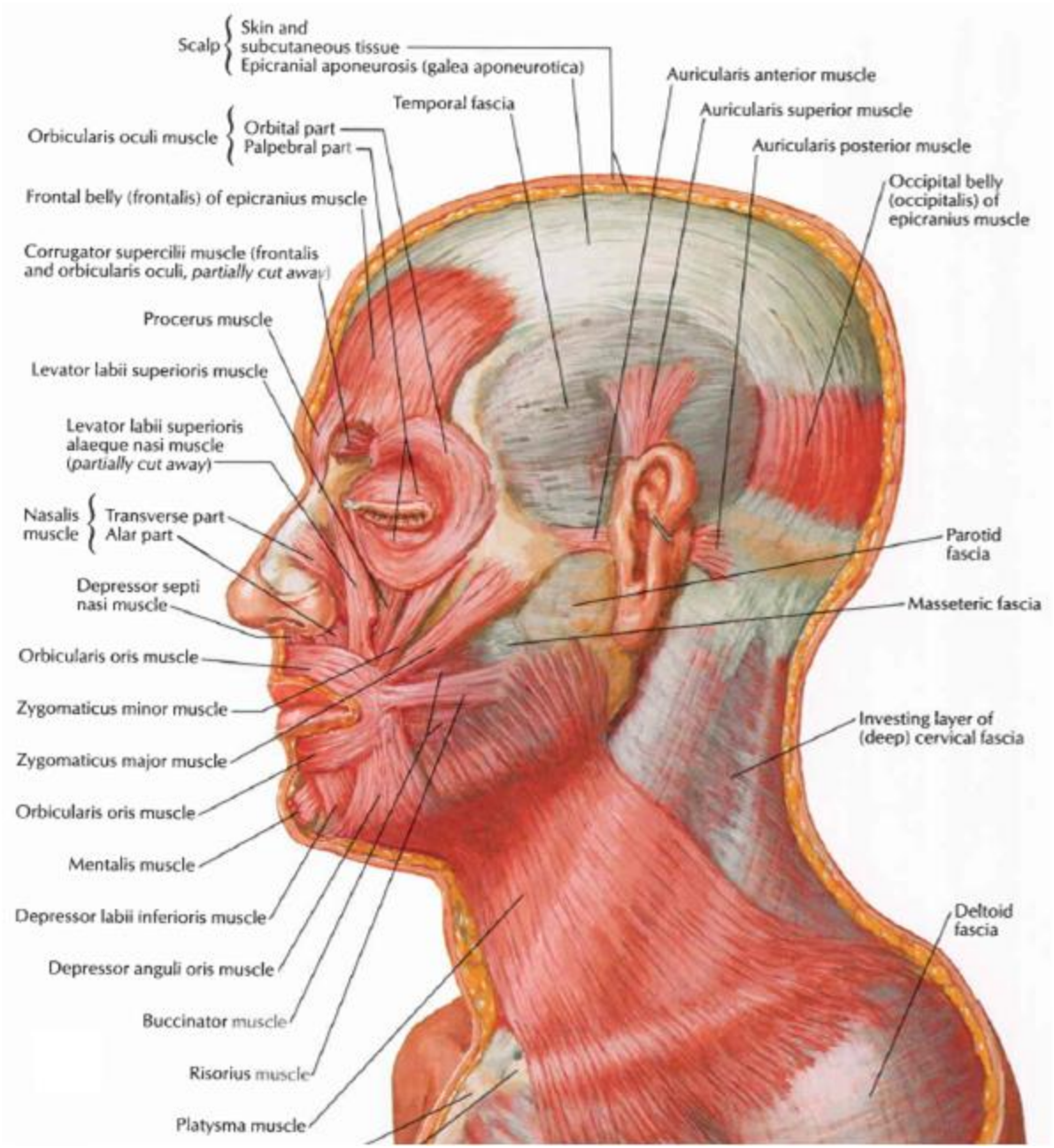
1.	M. nasalis	N. Facialis [VII]
2.	M. Depressor septi nasi	

Mulut

1.	M. Orbicularis oris	N. Facialis [VII]
2.	M. Buccinator	
3.	M. Depressor labii inferioris	
4.	M. Levator labii superioris	
5.	M. Mentalis	
6.	M. Tranversus menti	
7.	M. Depressor anguli oris	
8.	M. Risorius	
9.	M. Levator anguli oris	
10.	M. Zygomaticus mayor	
11.	M. Zygomaticus minor	
12.	M. Levator labii superioris alaque nasi	

Leher

1.	Platysma	N. Facialis [VII]
----	----------	-------------------



Otot-otot Lidah

1.	M. Longitudinalis superior	N. Hypoglossus [XII]
2.	M. Longitudinalis inferior	
3.	M. Transversus linguae	
4.	M. Genioglossus	
5.	M. Hyoglossus	
6.	M. Chondroglossus	
7.	M. Styloglossus	
8.	M. palatoglossus	N. Glossopharyngeus [IX] N. Vagus [X] N. Accesorius, radix cranialis [XI]

Otot Langit-langit

1.	M. Levator veli palatini	Plexus pharyngeus [IX,X]
2.	M. Tensor veli palatini	N. Musculi tensoris veli palatini dari N. Mandibularis [V/3]
3.	M. uvulae	Plexus pharyngeus dari N. Vagus [X], N. Glossopharyngeus [IX]

Otot-otot Tenggorok

1.	M. Cricothyroideus	N. Laryngeus superior dari N. Vagus [X]
2.	M. Cricoarytenoideus posterior	N. Laryngeus inferior dari N. Vagus [X]
3.	M. Cricoarytenoideus lateralis	
4.	M. Arytenoideus transversus	
5.	M. Arytenoideus obliquus	
6.	M. vocalis	
7.	M. thyroarytenoideus	
	Pars thyroepiglottica	

Otot Rongga Kerongkongan, Pharyng

Otot pengikat pharyng

1.	M. Constrictor pharyngis superior	Plexus pharyngeus dari N. Glossopharyngeus [IX]
----	-----------------------------------	---

Otot pengikat rongga kerongkongan

1.	M. Constrictor pharyngis medium	Plexus pharyngeus dari N. Glossopharyngeus [IX] dan N. Vagus [X]
2.	M. Constrictor pharyngis inferior	Plexus pharyngeus dari N. Vagus [X]

Otot pengangkat pharyng

1.	M. Palatopharyngeus	Plexus pharyngeus dari N. Glossopharyngeus [IX]
2.	M. Salpingopharyngeus	
3.	M. Stylopharyngeus	R. Musculi stylopharyngei dari N. Glossopharyngeus [IX]

Otot Leher Lateral

1.	M. sternocleidomastoideus	N. accesorius [XI], plexus cervicalis
----	---------------------------	---------------------------------------

Otot Tulang Lidah

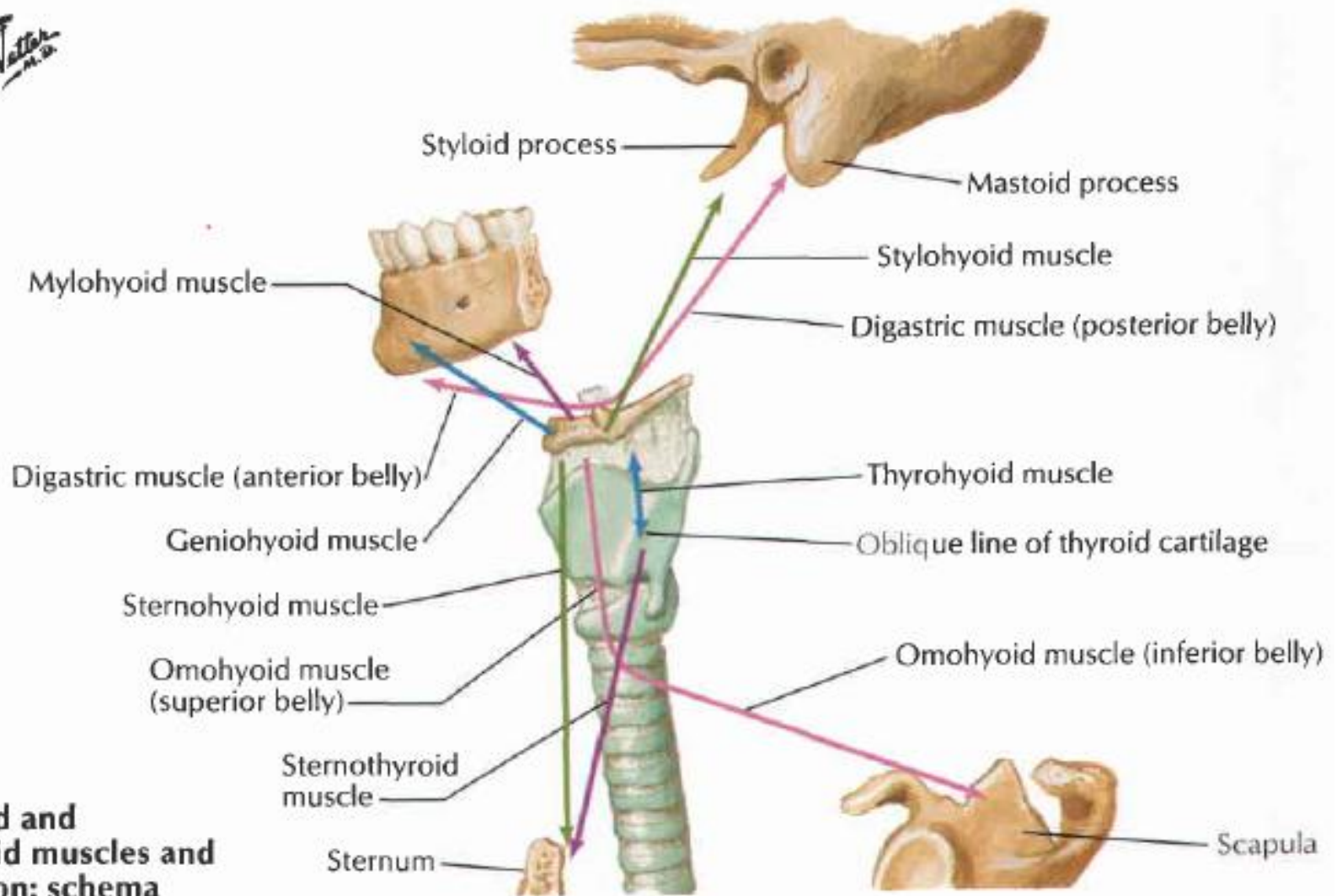
Atas

1.	M. digastricus	Venter anterior: N. Mylohyoideus (N. Mandubularis [V/3]) Venter posterior: R. Digastricus (N. Facialis [VII])
2.	M. stylohyoideus	N. Stylohyoideus (N. Facialis [VII])
3.	M. mylohyoideus	N. Mylohyoideus (N. Mandubularis [V/3])
4.	M. geniohyoideus	Ansa cervicalis

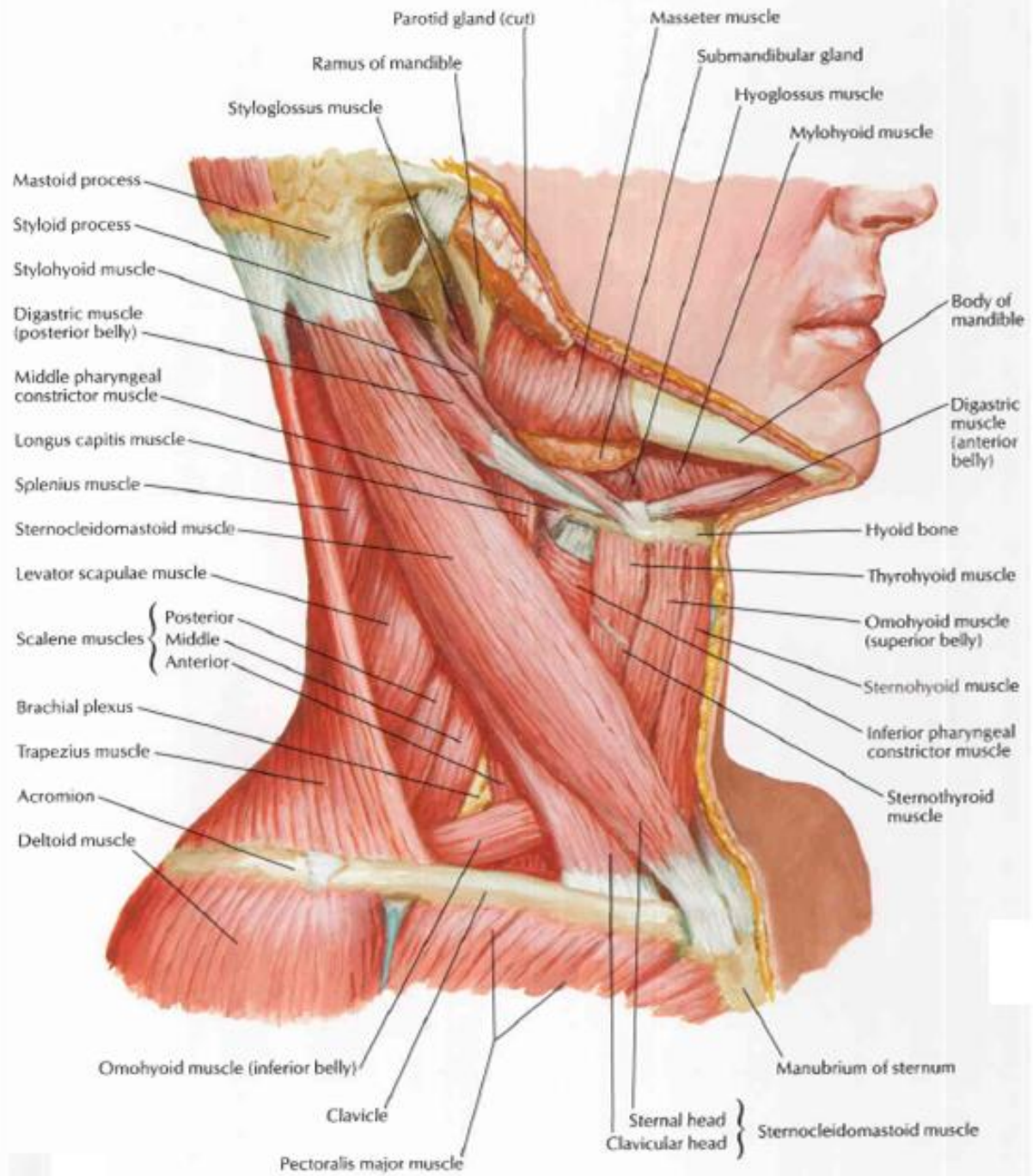
Bawah

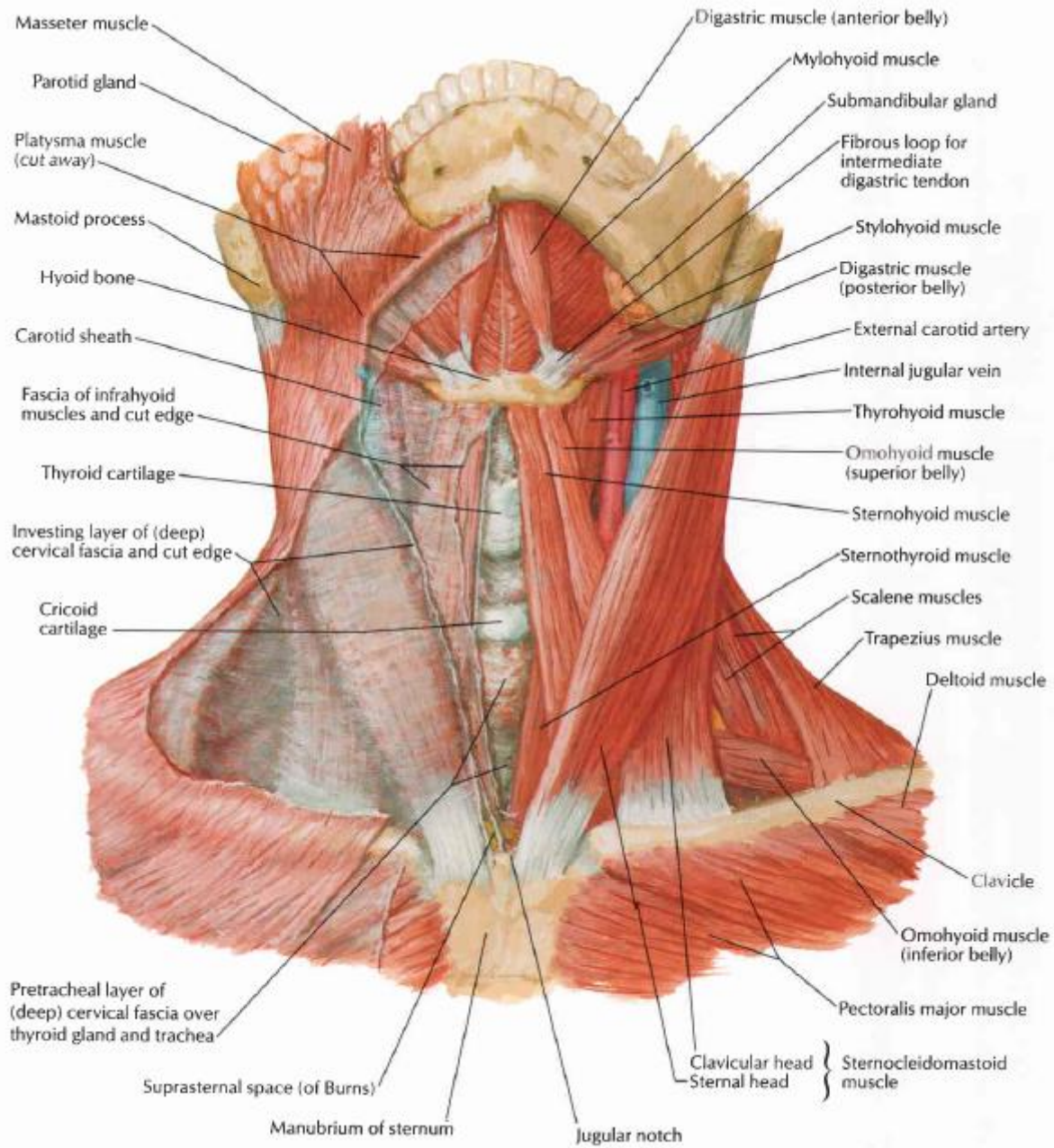
1.	M. Sternohyoideus	Ansa cervicalis (plexus cervicalis)
2.	M. Sternothyroideus	
3.	M. Thyrohyoideus	
4.	M. Omohyoideus	

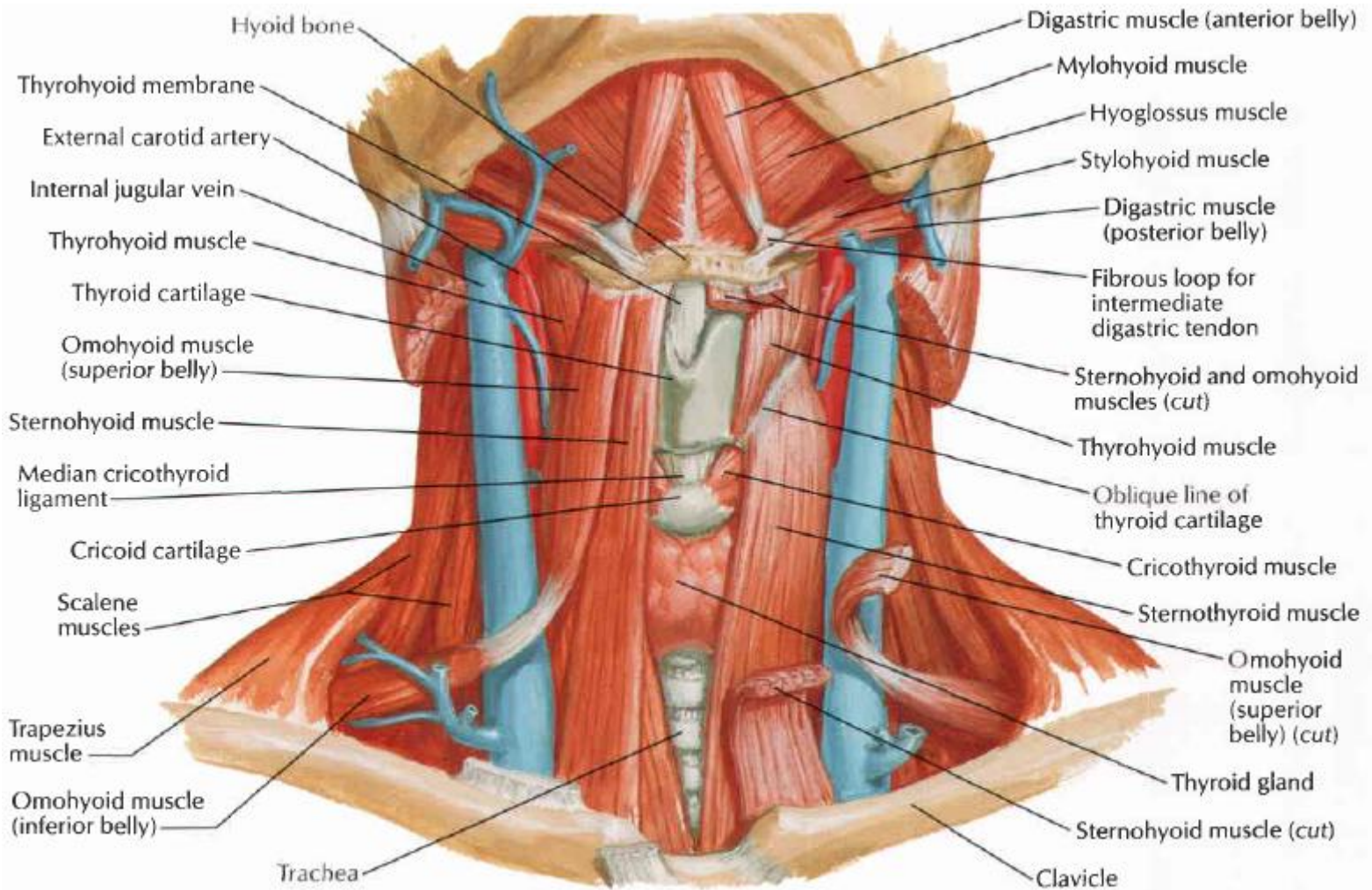
F. Natta
M.D.



Infrahyoid and suprahyoid muscles and their action: schema





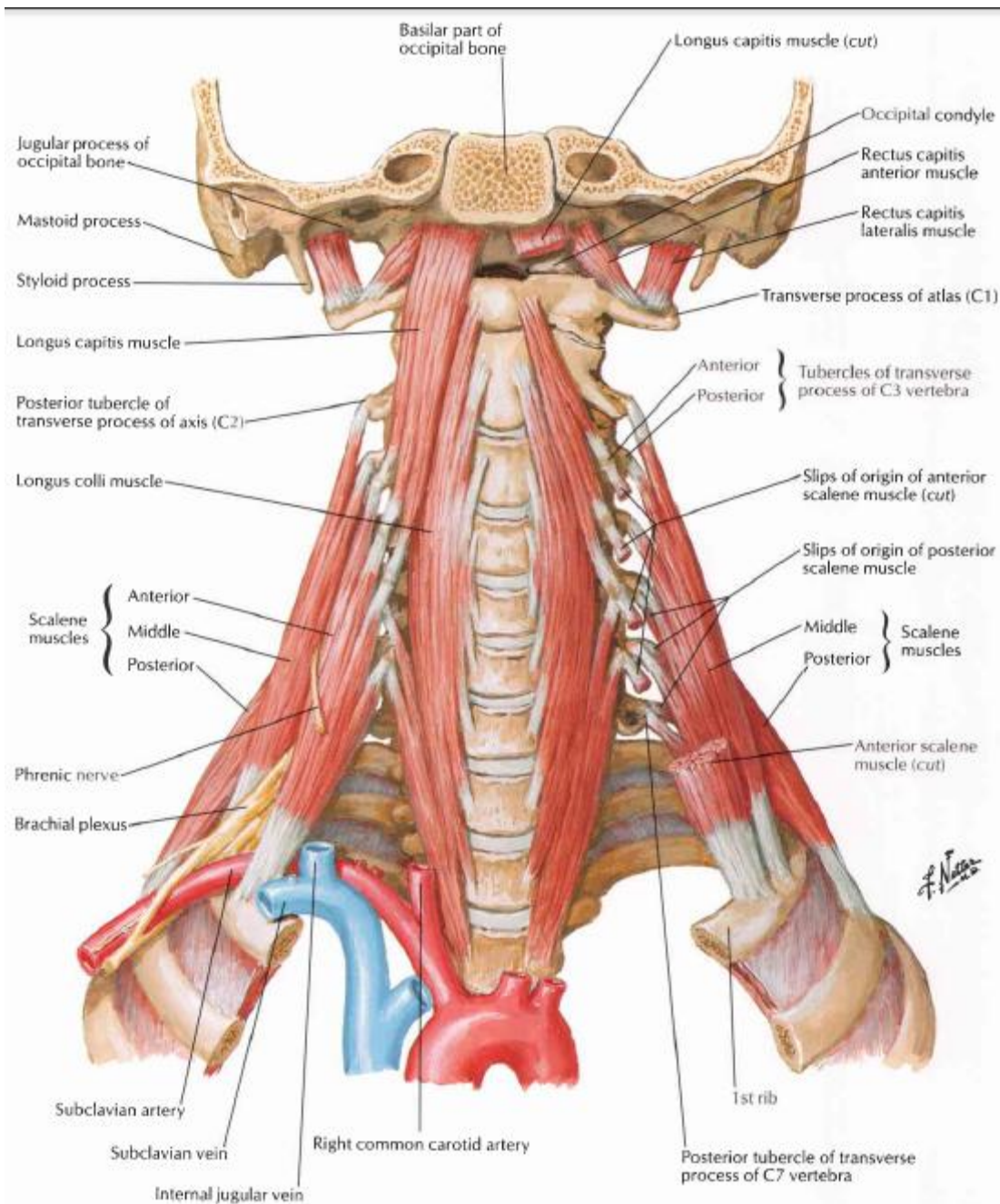


Otot Scalenus

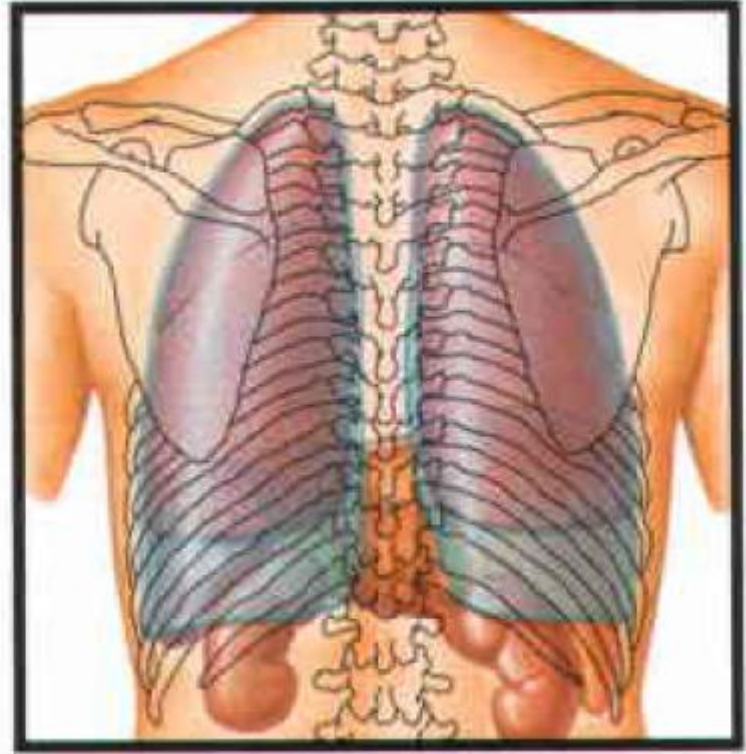
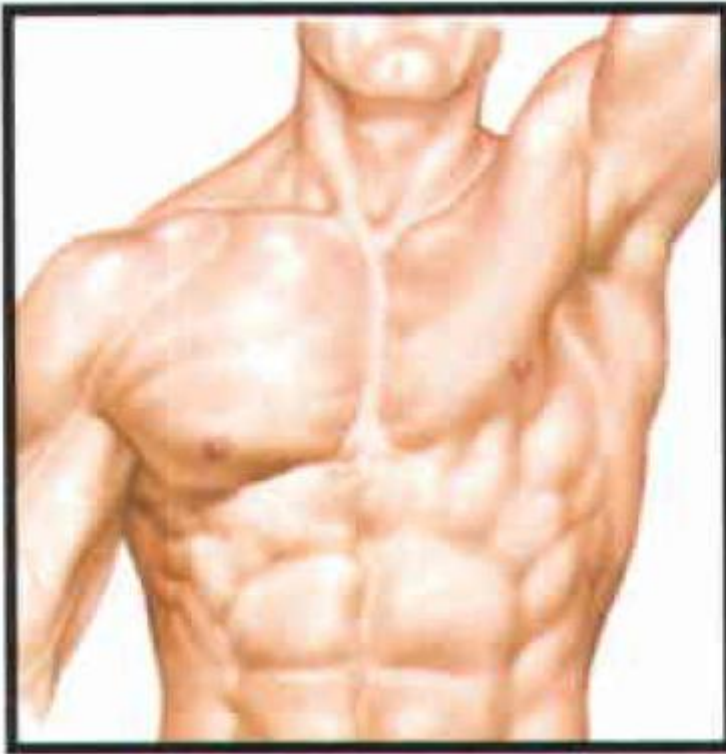
1.	M. Scalenus anterior	Cabang langsung pexus cervicalis dan plexus brachialis
2.	M. Scalenus medius	
3.	M. Scalenus posterior	

Otot Pravertebra

1.	M. Rectus capitis anterior	Rr. Ventrals plexus cervicalis
2.	M. Longus capitis	Cabang langsung pexus cervicalis
3.	M. Longus colli	



THORAX

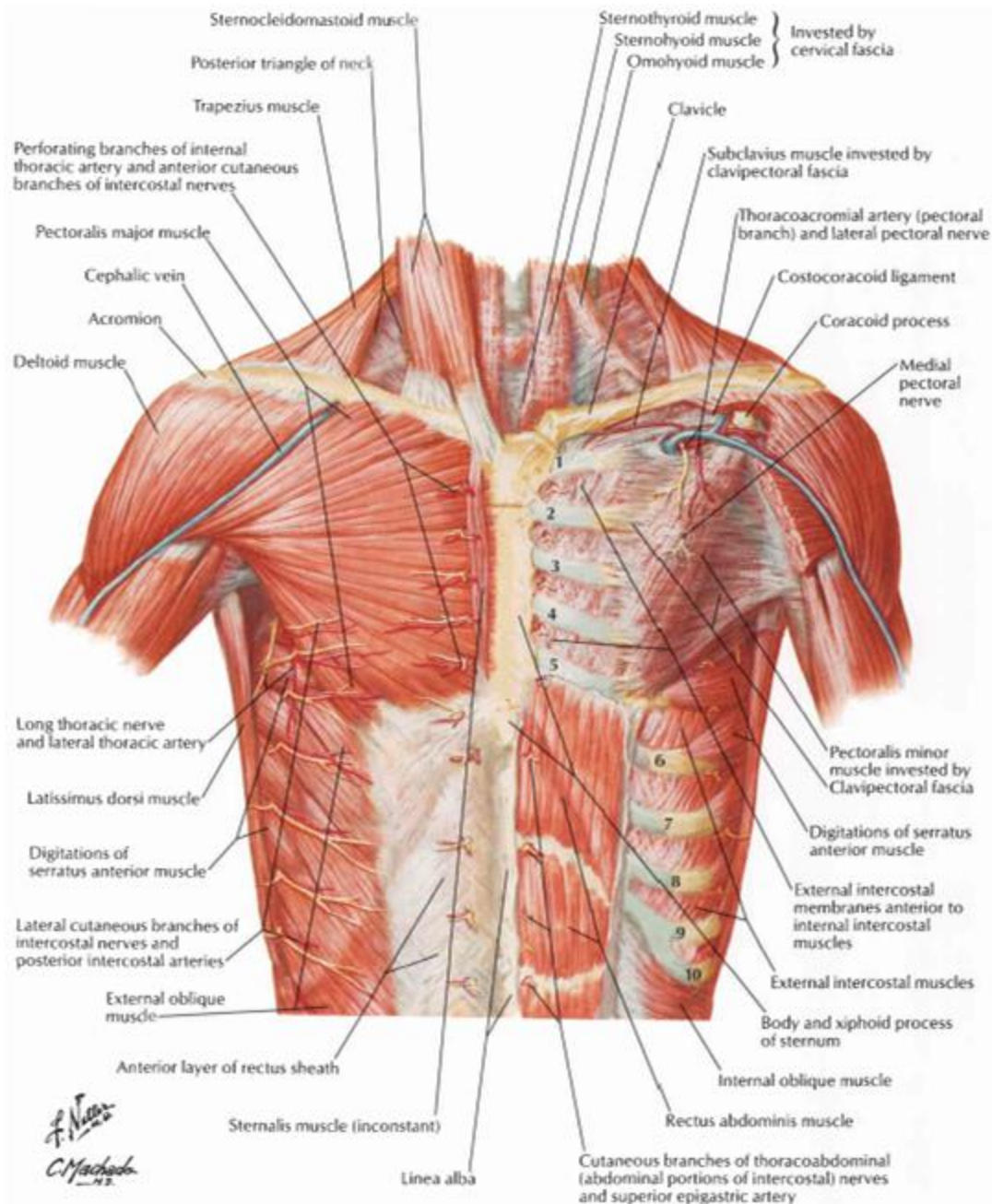


Otot Ventral Bahu

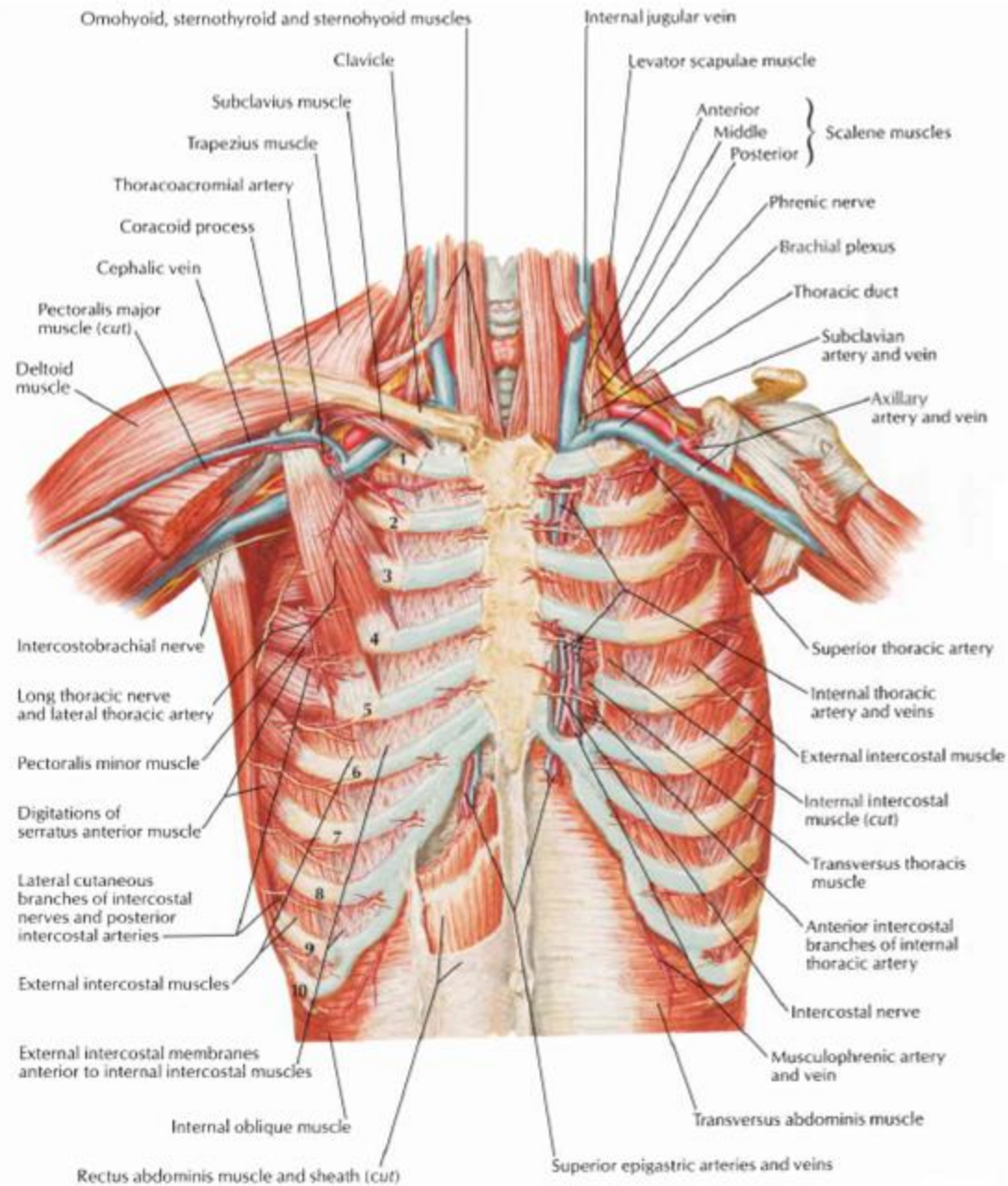
1.	M. Pectoralis major	Nn. Pectorales medialis et lateralis (plx. Brachialis, pars infra-/supraclavicularis)
2.	M. Pectoralis minor	
3.	M. Subclavius	N. Subclavius (plx. Brachialis, pars infraclavicularis)
4.	M. subscapularis	N. Subscapulares (plx. Brachialis, pars infraclavicularis)

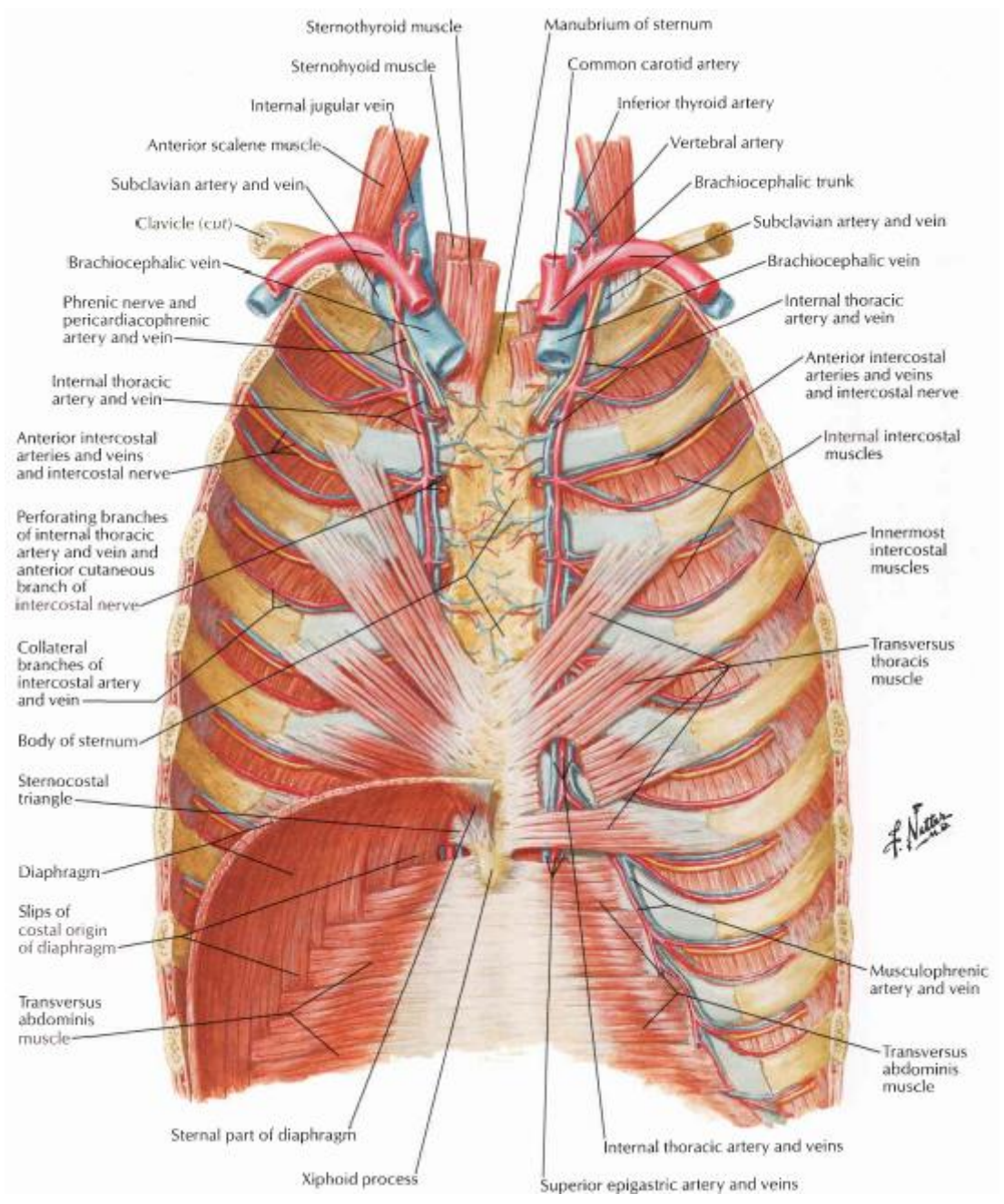
Otot Dinding Dada

1.	M. sternalis	Cabang Nn. Pectorales (plx. Brachialis, pars supraclavicularis) atau Nn. Intercostales (Nn. Thoracici)
2.	Mm. Intercostales externi	
3.	Mm. Intercostales interni	
4.	Mm. subcostales	
5.	M. Transversus thoracis	

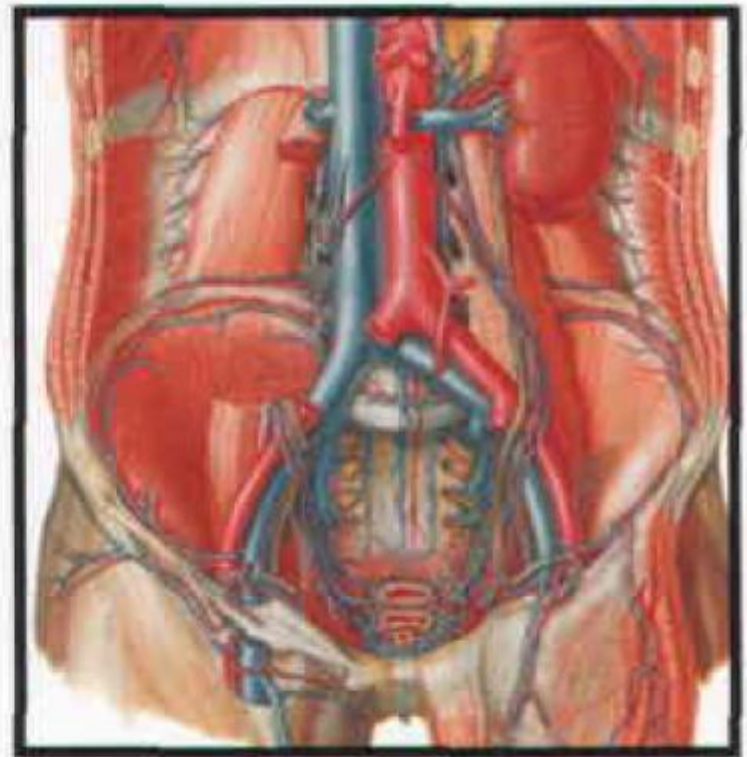
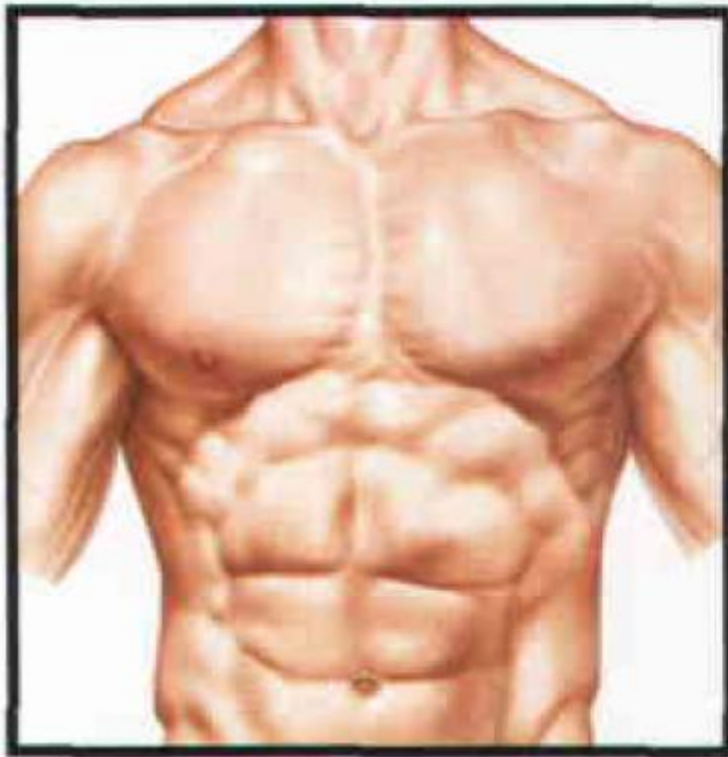


F. Netter
C. Machado
 1912





ABDOMEN



Otot Dinding Perut

Anterior

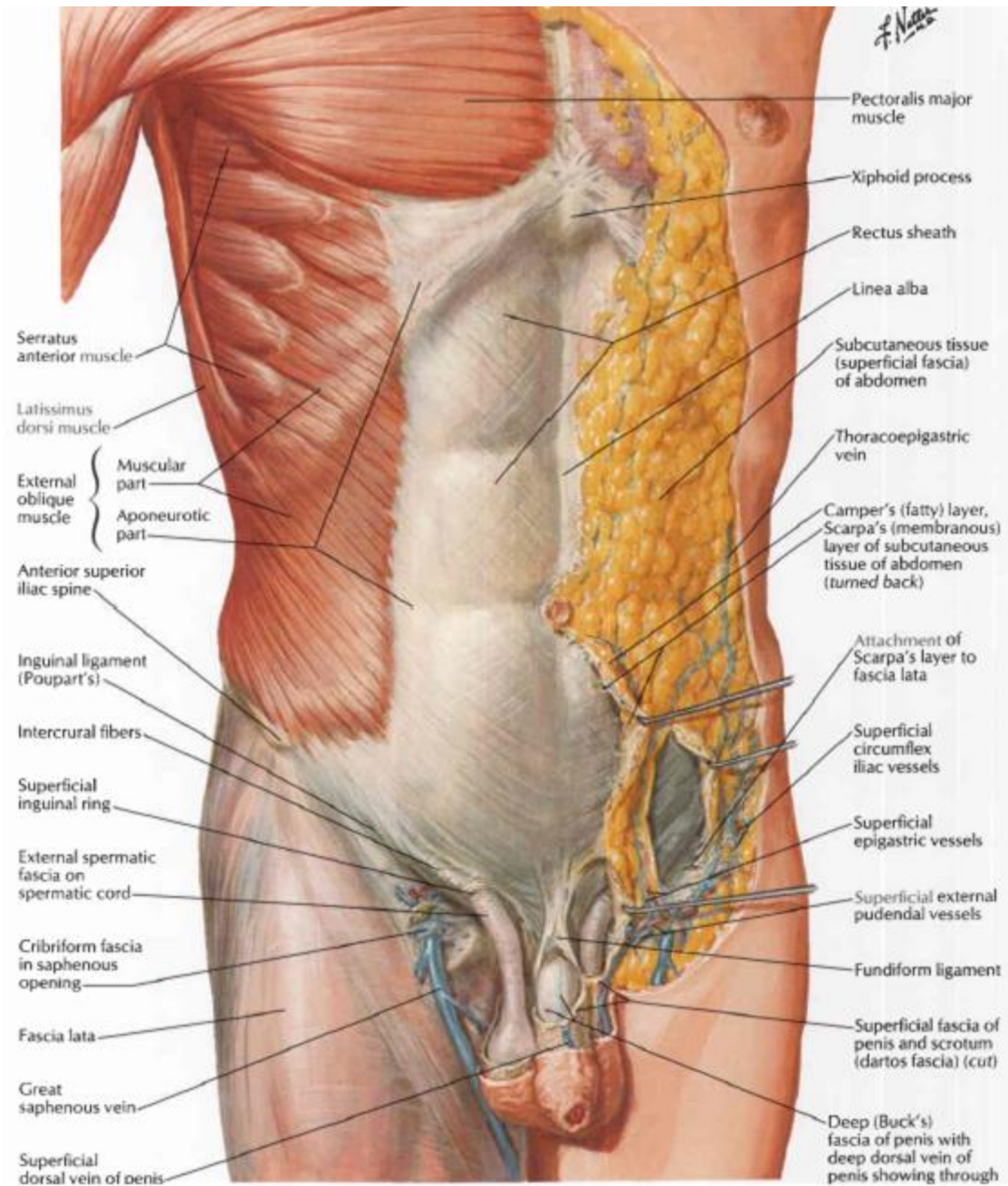
- | | | |
|----|---------------------|--|
| 1. | M. Rectus abdominis | Nn. Intercostales (Nn. Thoracici) |
| 2. | M. pyramidalis | Nn. Intercostales kaudal (Nn. Thoracici) |

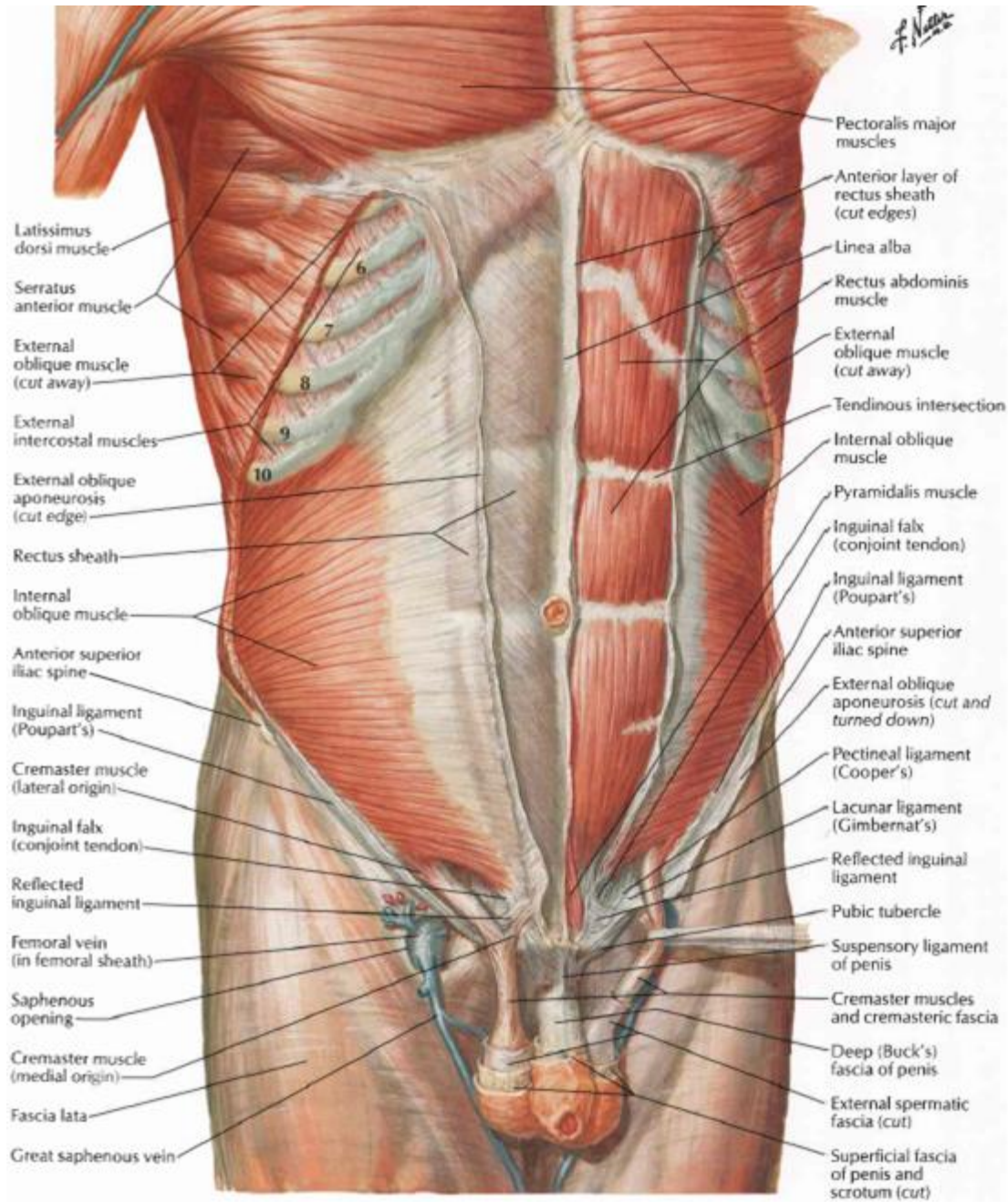
Lateral

- | | | |
|----|--------------------------------|--|
| 1. | M. Obliquus externus abdominis | Nn. Intercostales kaudal (Nn. Thoracici); N. Iliohypogastricus; ilioinguinalis (plx. Lumbalis) |
| 2. | M. Obliquus internus abdominis | |
| 3. | M. Transversus abdominis | Nn. Intercostales kaudal (Nn. Thoracici); N. Iliohypogastricus; ilioinguinalis (plx. Lumbalis); N. genitofemoralis |

Posterior

- | | | |
|----|-----------------------|--|
| 1. | M. Quadratus lumborum | Rr. Musculares (plx. Lumbalis); N. Intercostalis (N. Thoracicus [T12]) |
|----|-----------------------|--|

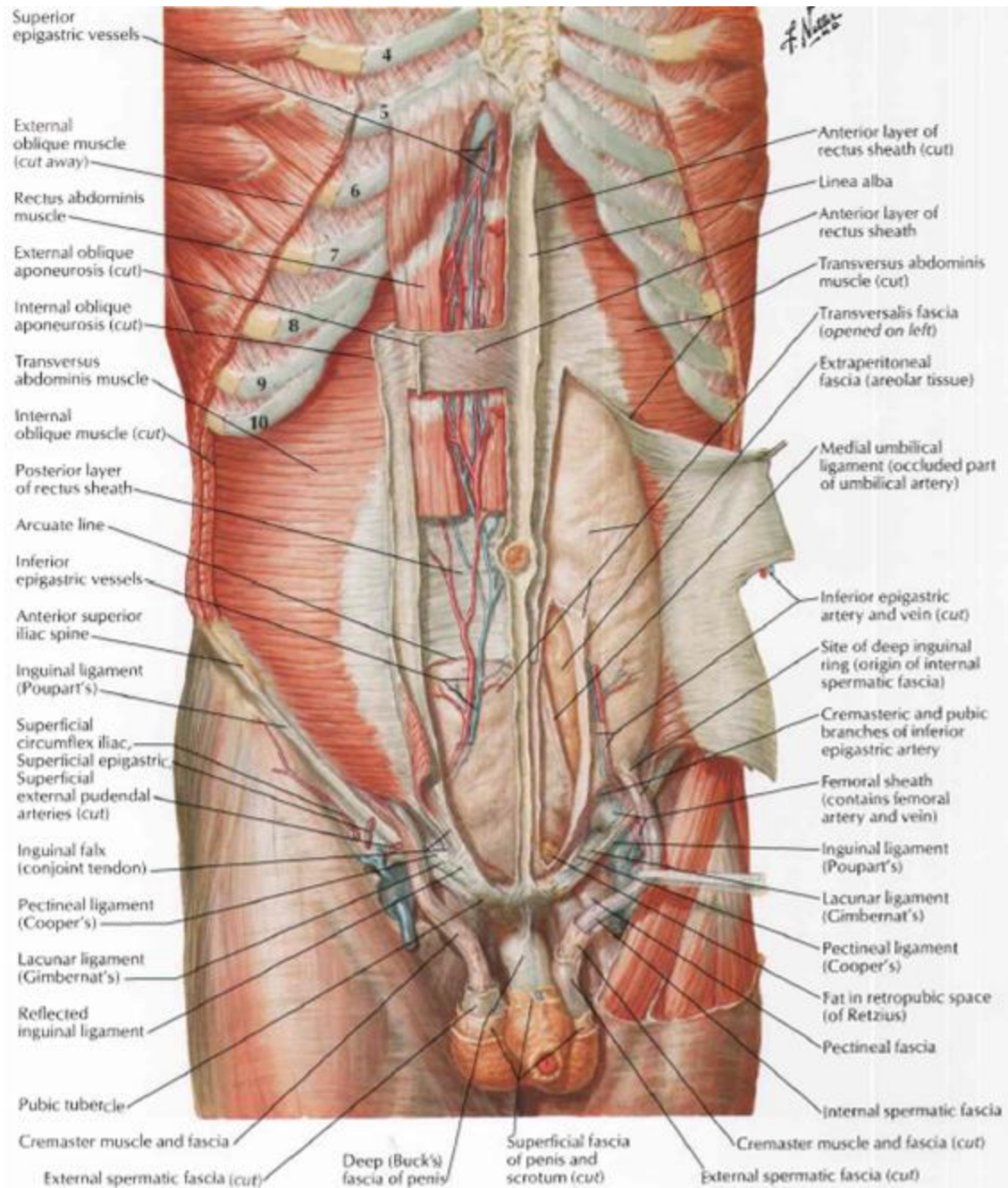


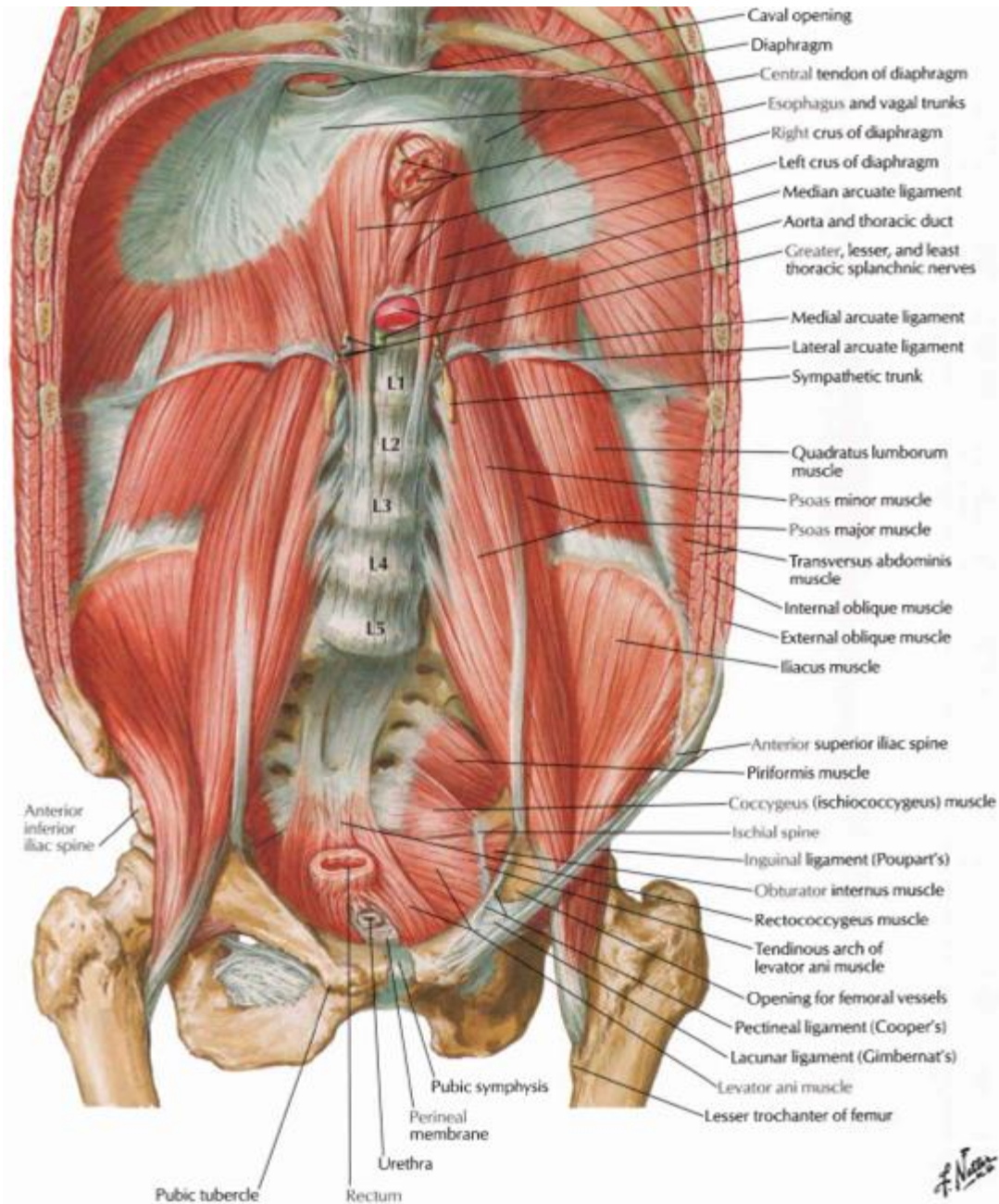


Latissimus dorsi muscle
Serratus anterior muscle
External oblique muscle (cut away)
External intercostal muscles
External oblique aponeurosis (cut edge)
Rectus sheath
Internal oblique muscle
Anterior superior iliac spine
Inguinal ligament (Poupart's)
Cremaster muscle (lateral origin)
Inguinal falx (conjoint tendon)
Reflected inguinal ligament
Femoral vein (in femoral sheath)
Saphenous opening
Cremaster muscle (medial origin)
Fascia lata
Great saphenous vein

6
7
8
9
10

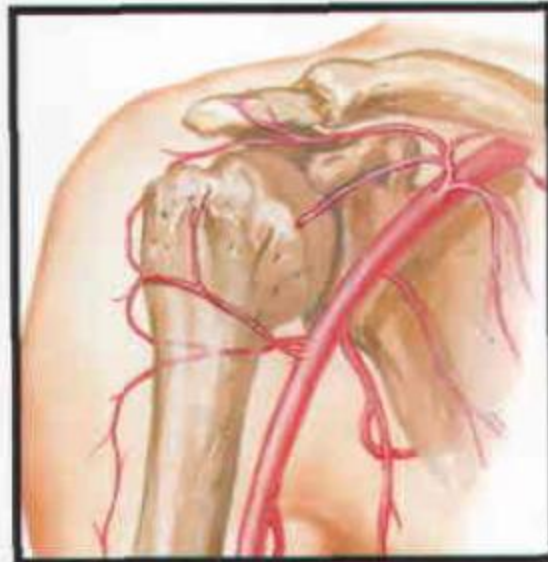
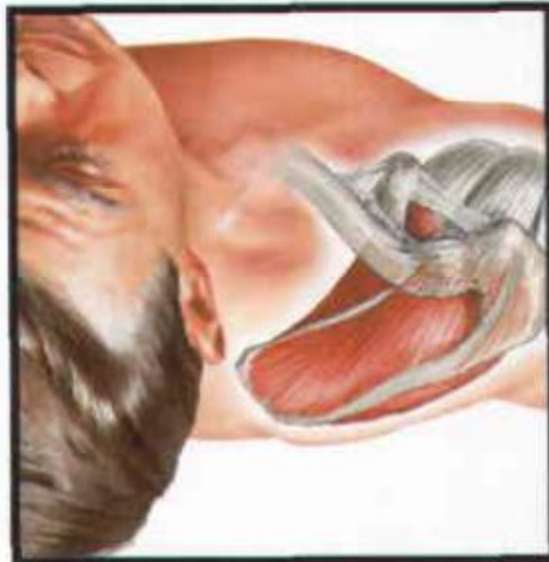
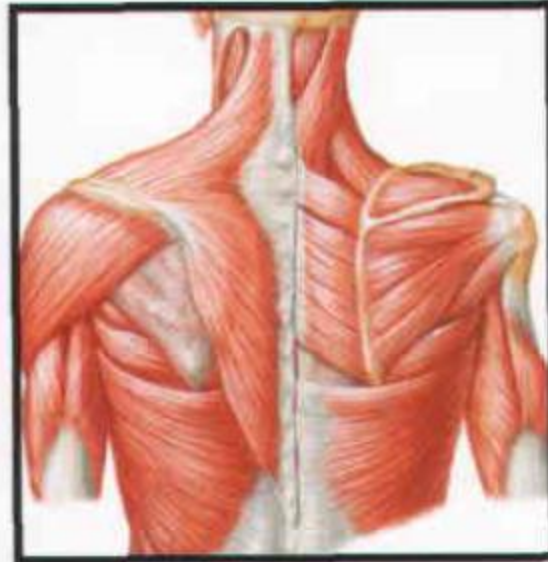
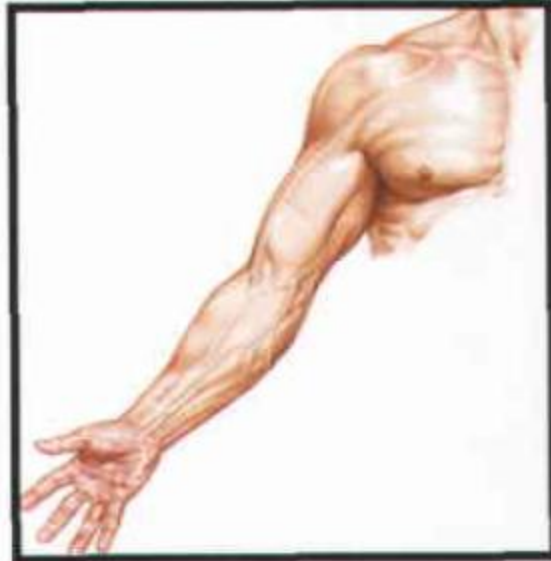Pectoralis major muscles
Anterior layer of rectus sheath (cut edges)
Linea alba
Rectus abdominis muscle
External oblique muscle (cut away)
Tendinous intersection
Internal oblique muscle
Pyramidalis muscle
Inguinal falx (conjoint tendon)
Inguinal ligament (Poupart's)
Anterior superior iliac spine
External oblique aponeurosis (cut and turned down)
Pectineal ligament (Cooper's)
Lacunar ligament (Gimbernat's)
Reflected inguinal ligament
Pubic tubercle
Suspensory ligament of penis
Cremaster muscles and cremaster fascia
Deep (Buck's) fascia of penis
External spermatic fascia (cut)
Superficial fascia of penis and scrotum (cut)





Handwritten signature

EKSTREMITAS SUPERIOR



Otot Punggung ke Gelang Bahu

1.	M. trapezius	N. Accesorius [XI] dan cabang langsung plx.cervicalis
2.	M. Levator scapulae	cabang langsung plx.cervicalis dan N. Dorsalis scapulae (plx. Brachialis, pars supraclavicularis)
3.	M. Rhomboideus major	N. Dorsalis scapulae (plx. Brachialis, pars supraclavicularis)
4.	M. Rhomboideus minor	
5.	M. Serratus anterior	N. Thoracicus longus (plx. Brachialis, pars supraclavicularis)

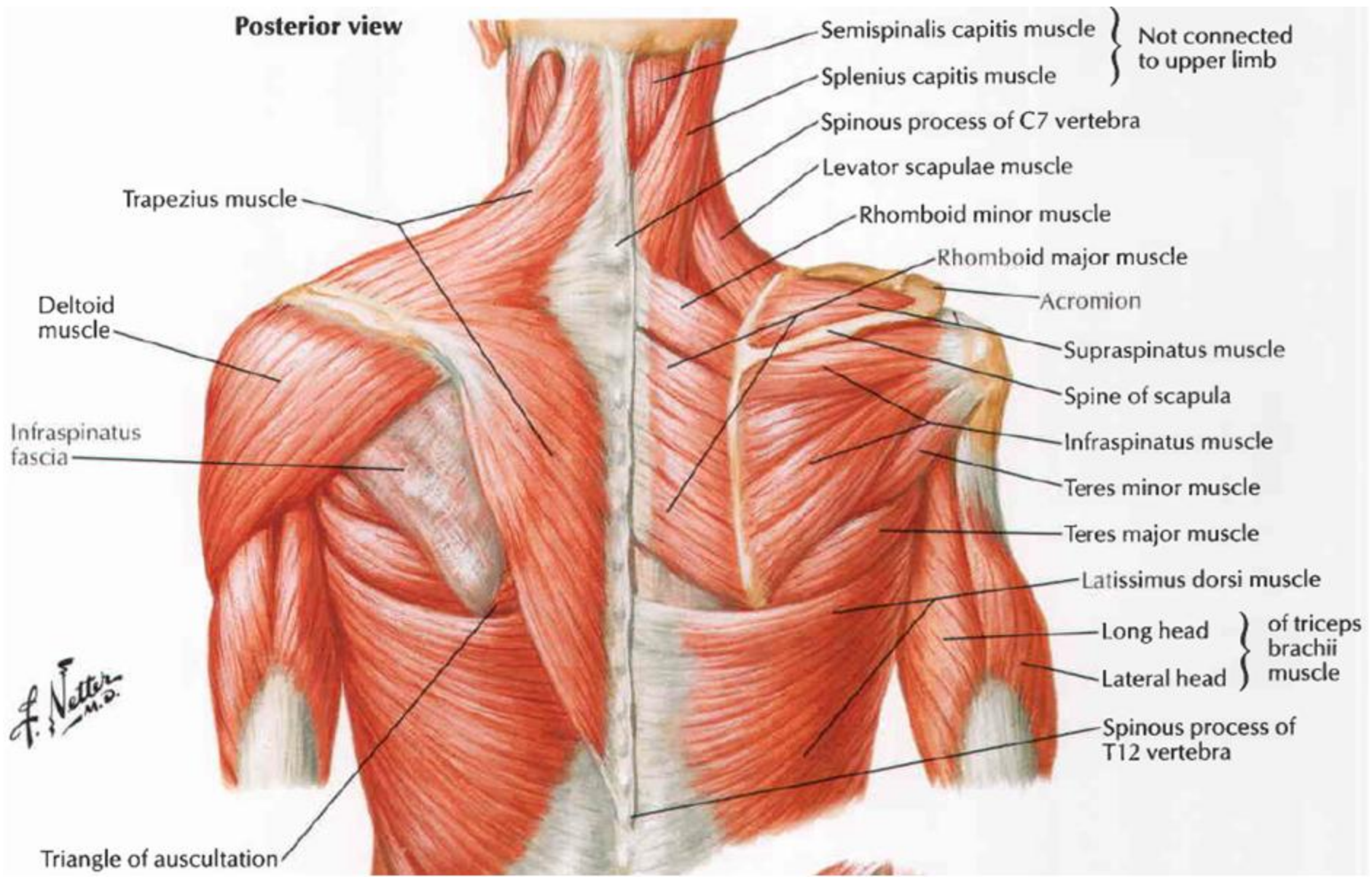
Otot Punggung ke Lengan

1.	M. Lattisimus dorsi	N. Thoracodorsalis (plx. Brachialis, pars supraclavicularis)
----	---------------------	--

Otot spinokostal

1.	M. Serratus posterior superior	Cabang ventral N. Cervicalis [C6] sampai N. Thoracicus [T2]
2.	M. Serratus posterior inferior	Cabang ventral N. Thoracicus [T11] sampai N. Lumbalis [L2]

Posterior view



Semispinalis capitis muscle } Not connected to upper limb
Splenius capitis muscle }

Spinous process of C7 vertebra
Levator scapulae muscle

Trapezius muscle

Rhomboid minor muscle
Rhomboid major muscle

Deltoid muscle

Acromion

Infraspinatus fascia

Supraspinatus muscle

Spine of scapula

Infraspinatus muscle

Teres minor muscle

Teres major muscle

Latissimus dorsi muscle

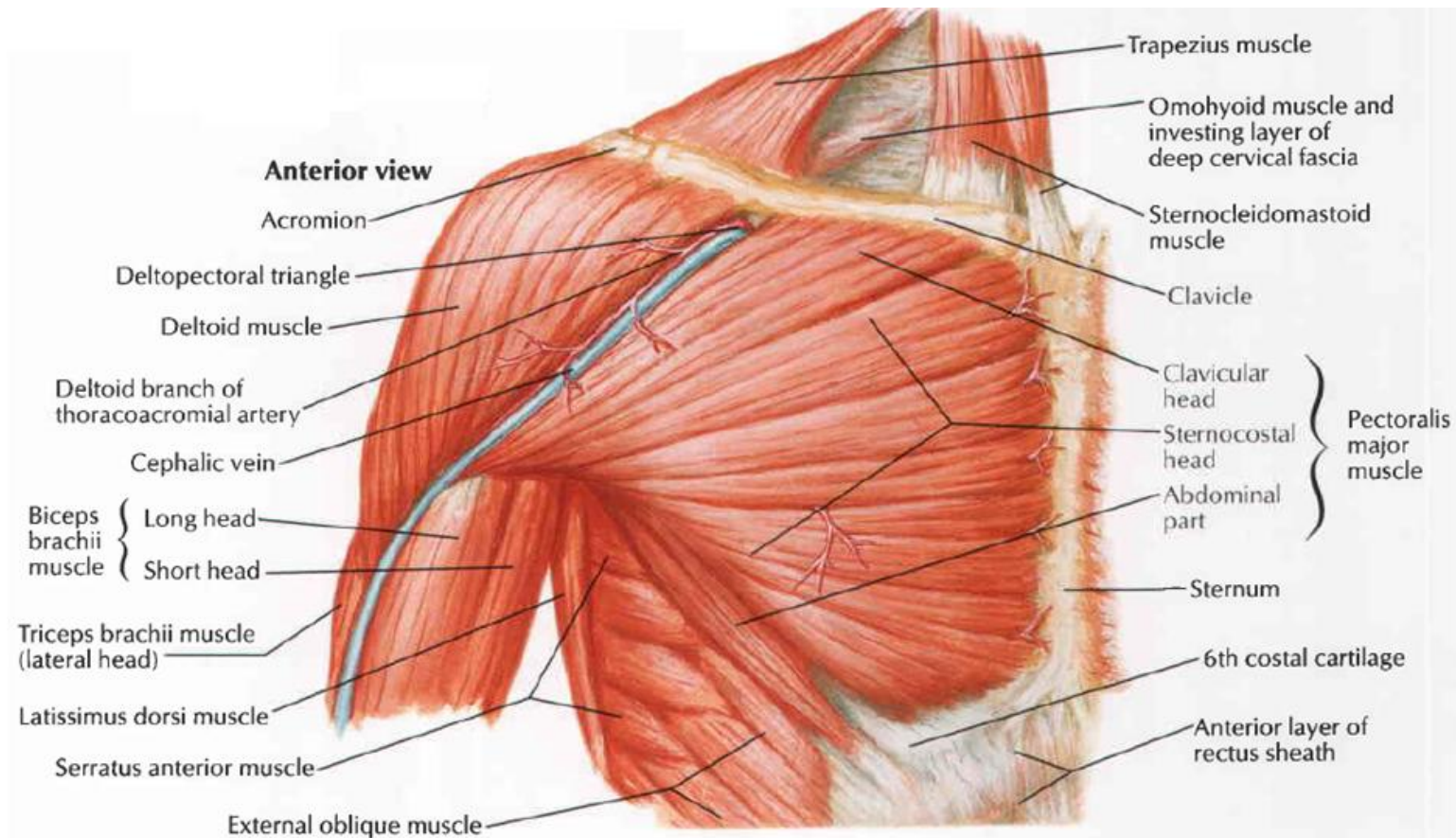
Long head } of triceps brachii muscle
Lateral head }

Spinous process of T12 vertebra

Triangle of auscultation

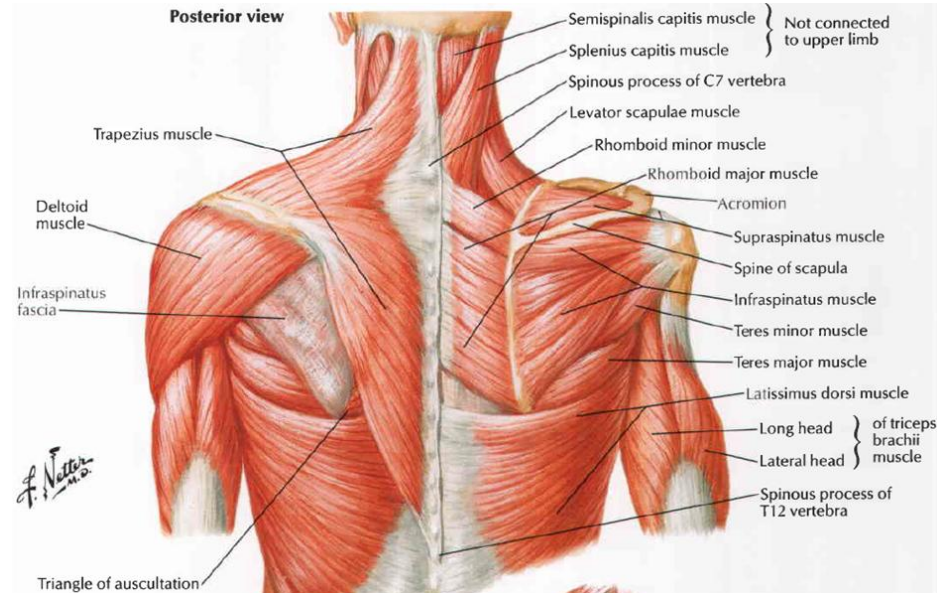
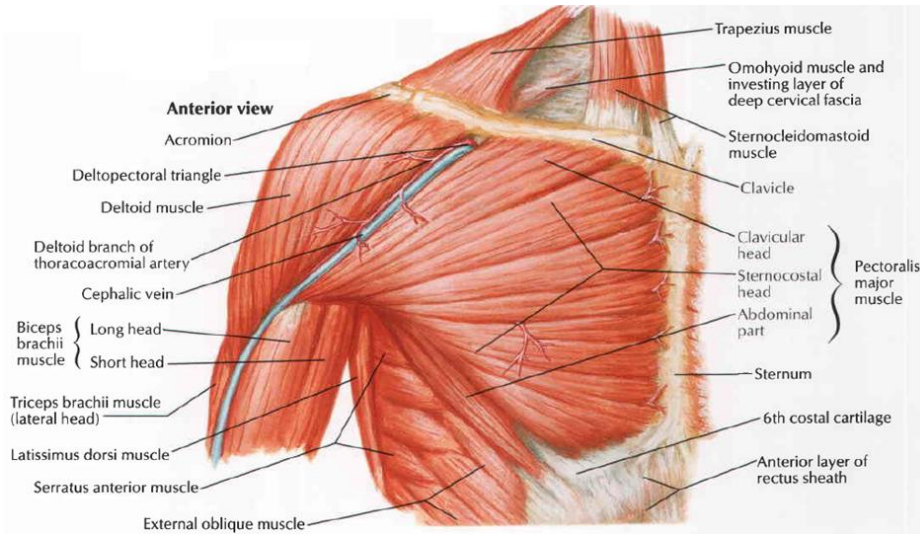
F. Netter M.D.

Otot Ventral Bahu		
1.	M. Pectoralis mayor	Nn. Pectoralis medialis et lateralis (plexus brachialis, pars infra-/supraclavicularis)
2.	M. Pectoralis minor	
3.	M. Subclavius	N. Subclavius (plexus brachialis, pars supraclavicularis)
4.	M. subscapularis	N. Subscapularis (plexus brachialis, pars infraclavicularis)



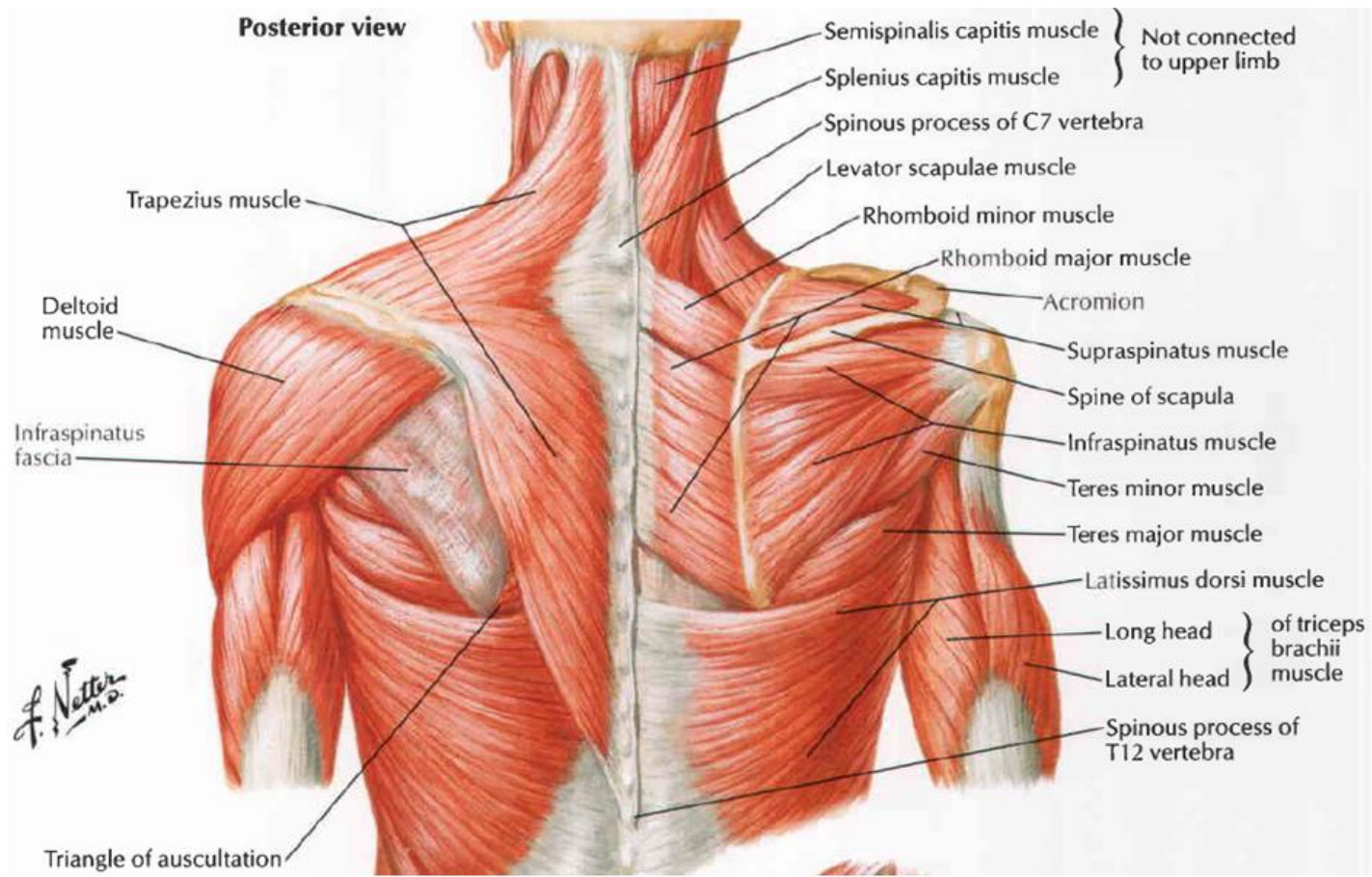
Otot Lateral Bahu

- | | | |
|----|------------------|--|
| 1. | M. deltoideus | N. Axillaris (plexus brachialis, pars infraclavicularis) |
| 2. | M. supraspinatus | N. Suprascapularis (plexus brachialis, pars supraclavicularis) |



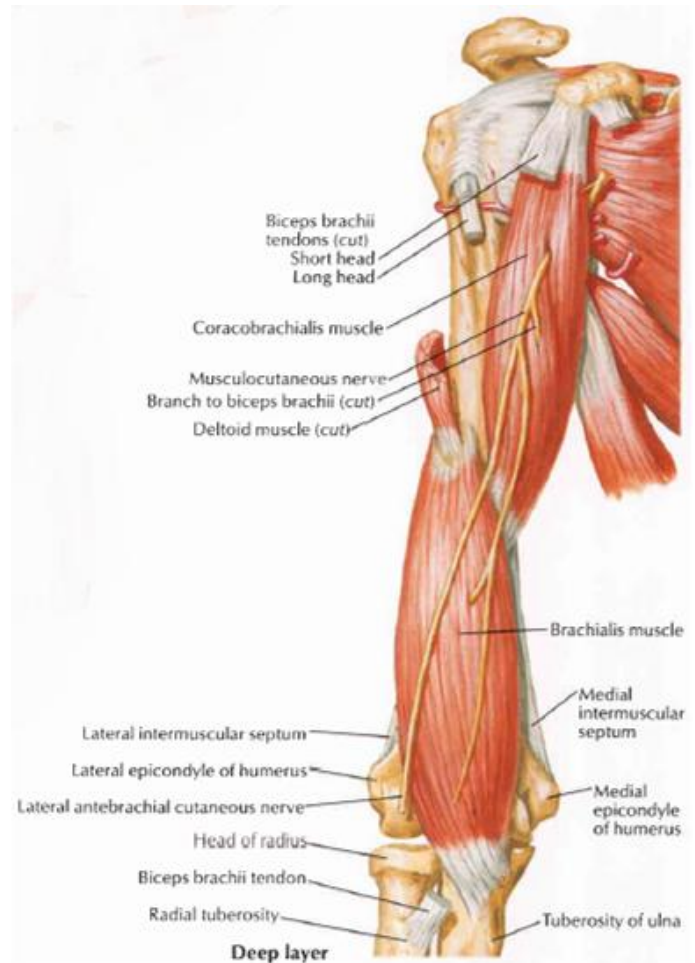
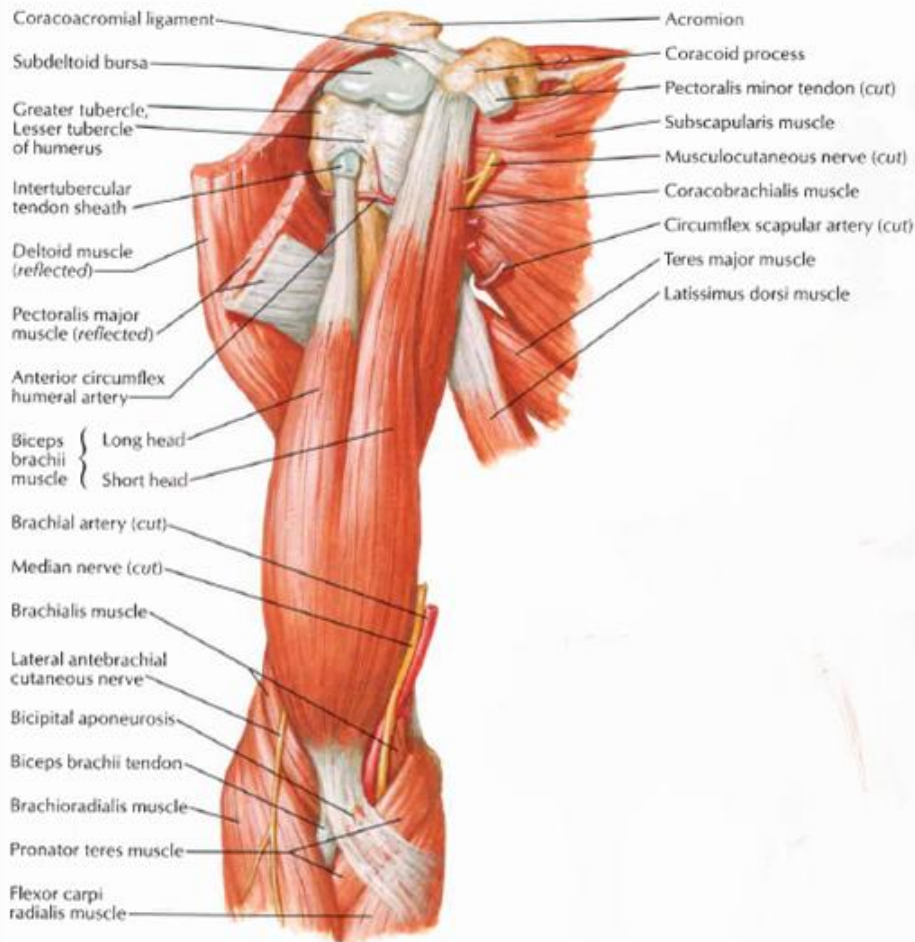
Otot Dorsal Bahu

1.	M. Infraspinatus	N. Suprascapularis (plexus brachialis, pars supraclavicularis)
2.	M. Teres minor	N. Axillaris (plexus brachialis, pars infraclavicularis)
3.	M. Teres major	Nn. Subscapulares atau N. Thoracodorsalis (plexus brachialis, pars infraclavicularis)
4.	M. Lattisimus dorsi	N. Thoracodorsalis (plexus brachialis, pars infraclavicularis)



Otot Ventral Lengan Atas

1.	M. Biceps brachii	N. Musculocutaneus (plexus brachialis, pars infraclavicularis)
2.	M. Coracobrachialis	
3.	M. brachialis	

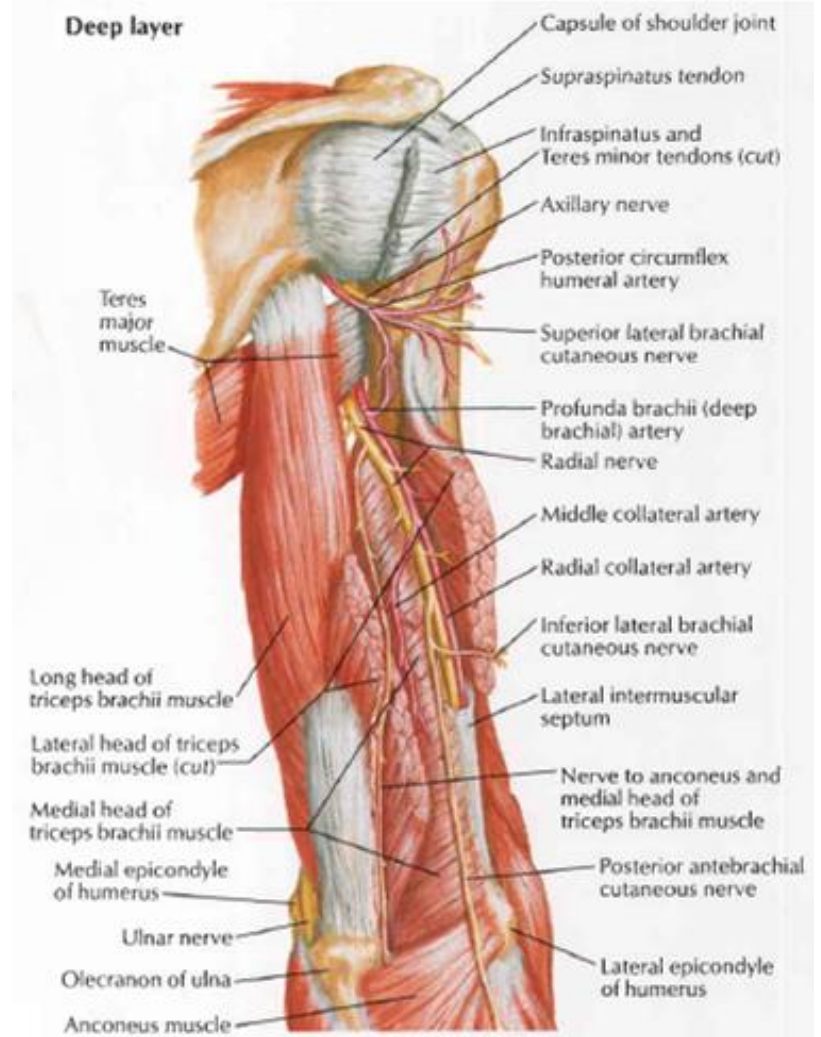
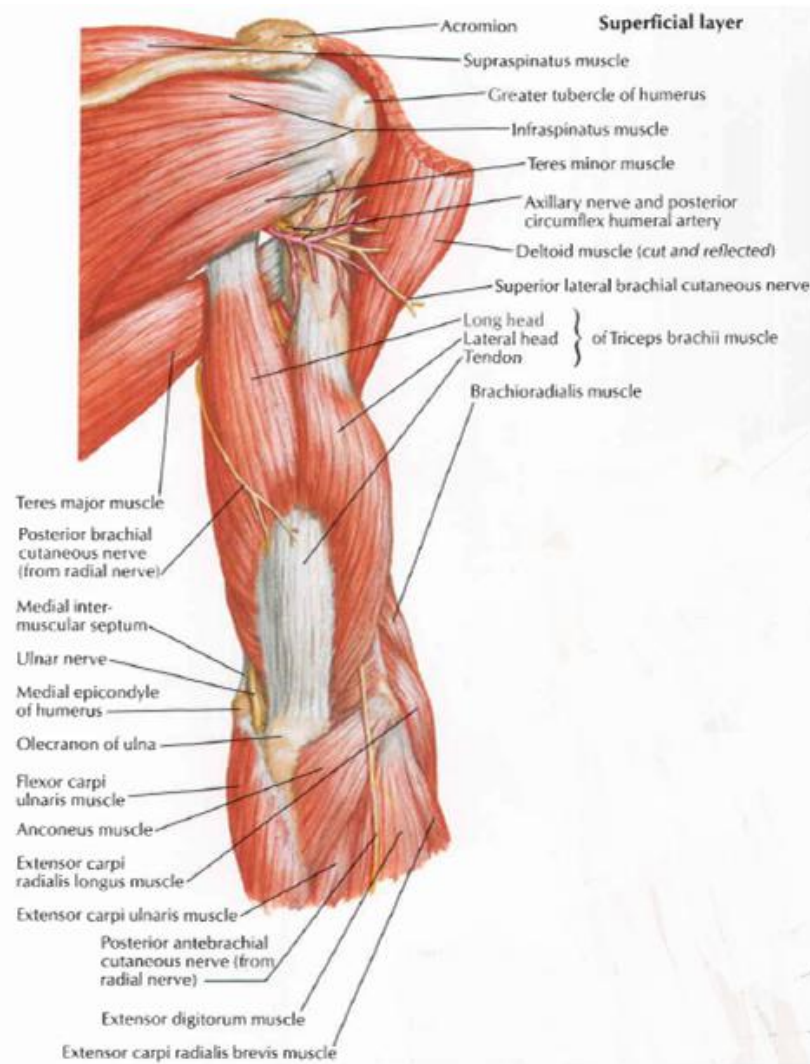


Otot Dorsal Lengan Atas

1. M. Triceps brachii

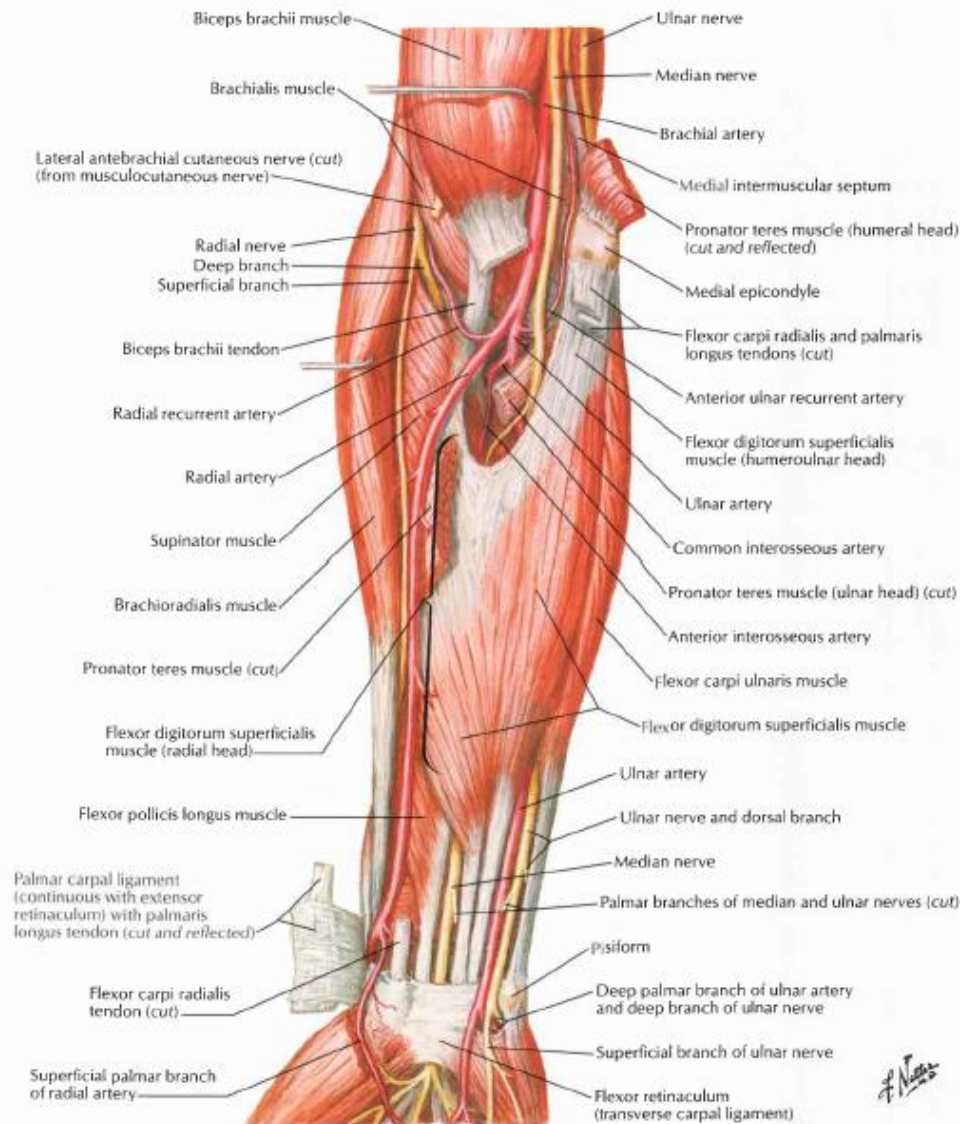
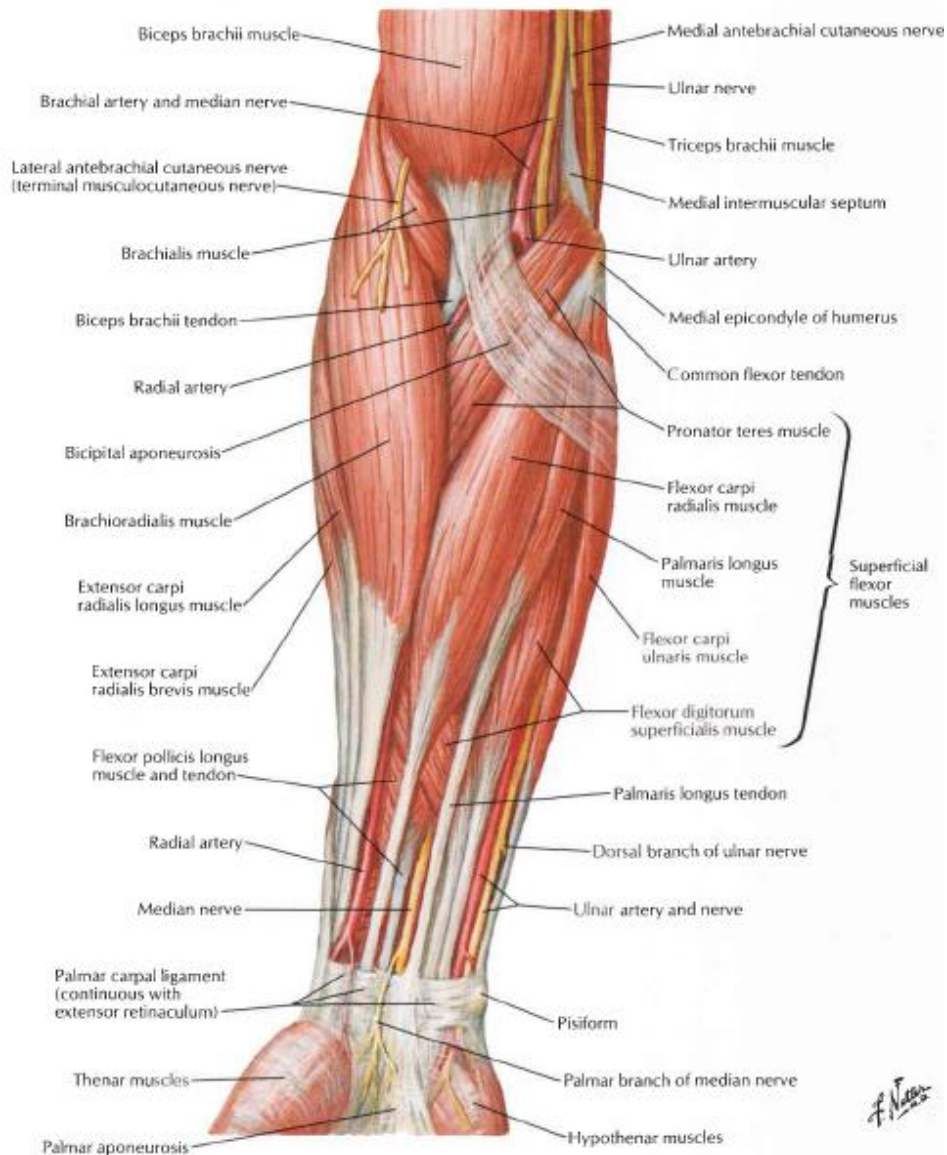
2. M. anconeus

N. Radialis (plexus brachialis, pars infraclavicularis)



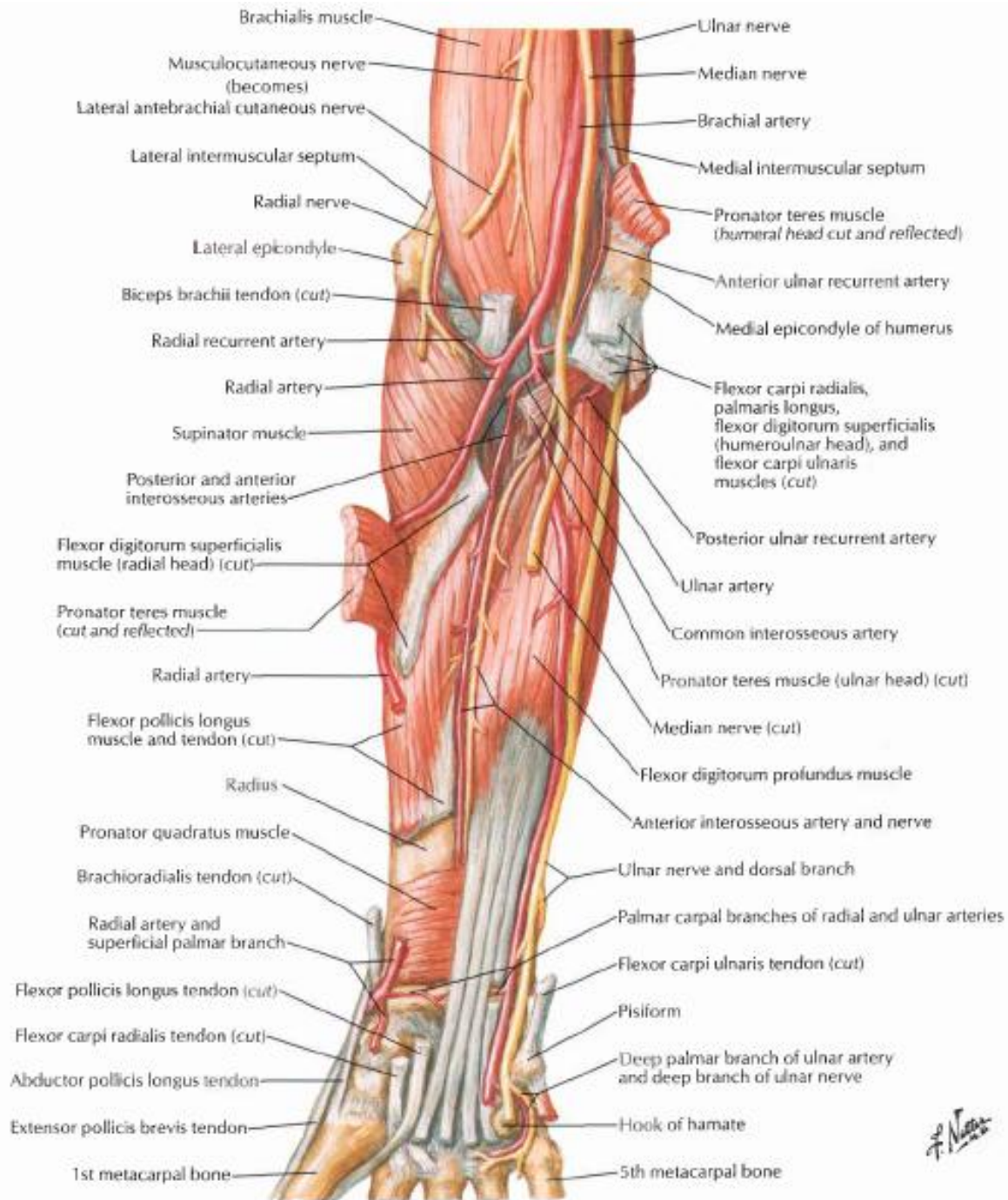
Otot Ventral Lengan Bawah

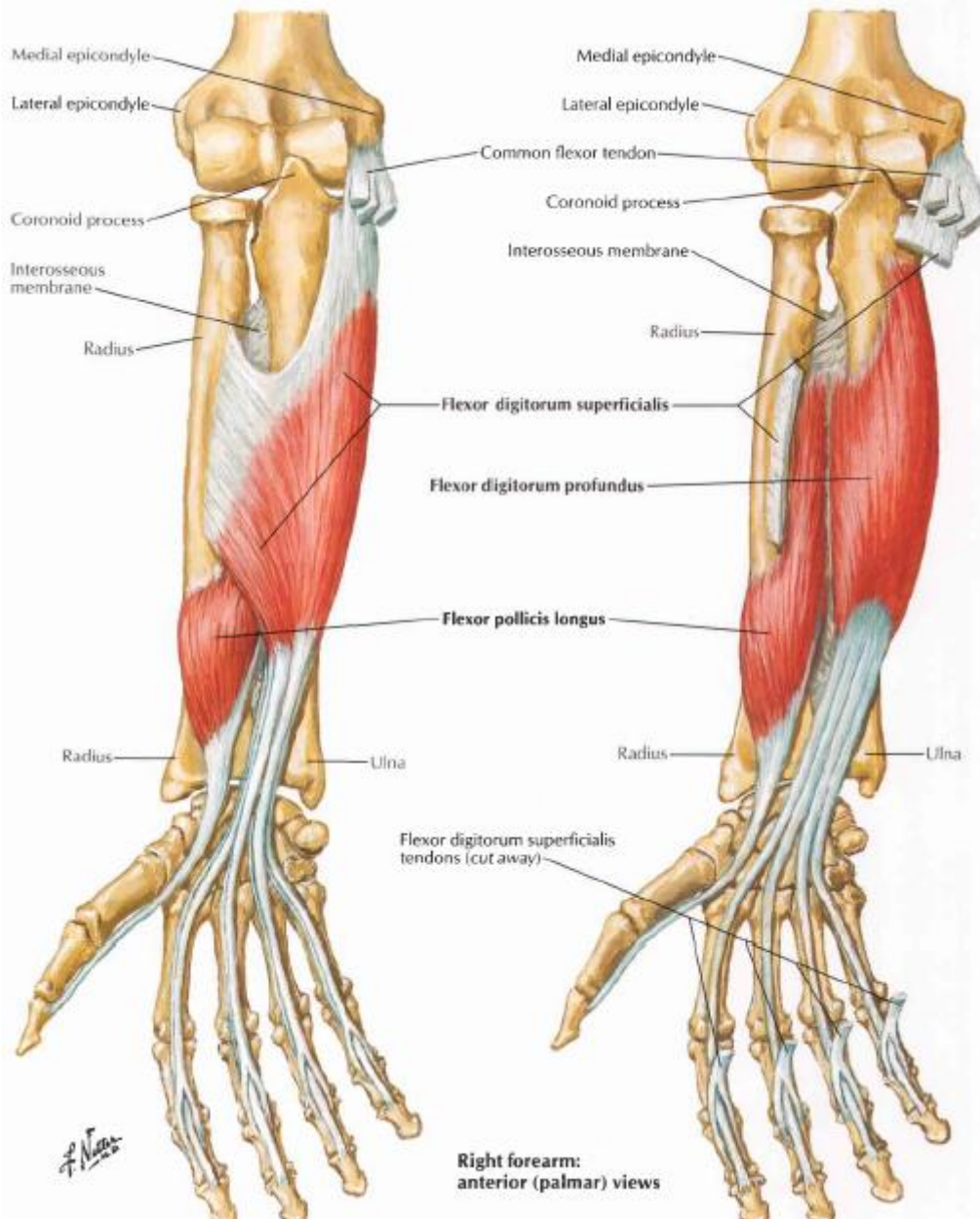
Superficial		
1.	M. Pronator teres	N. Medianus (plexus brachialis, pars infraclavicularis)
2.	M. Palmaris longus	
3.	M. Flexor digitorum superficialis	
4.	M. Flexor carpi radialis	
5.	M. Flexor carpi ulnaris	N. Ulnaris (plexus brachialis, pars infraclavicularis)
Profunda		
1.	M. Flexor digitorum profundus	N. Ulnaris [bag. Ulnar] dan N. Medianus [bag. Radial] (plexus brachialis, pars infraclavicularis)
2.	M. Flexor pollicis longus (plexus brachialis, pars infraclavicularis)	N. Medianus (plexus brachialis, pars infraclavicularis)
3.	M. Pronator quadratus	N. Interosseus anterior (plexus brachialis, pars infraclavicularis)



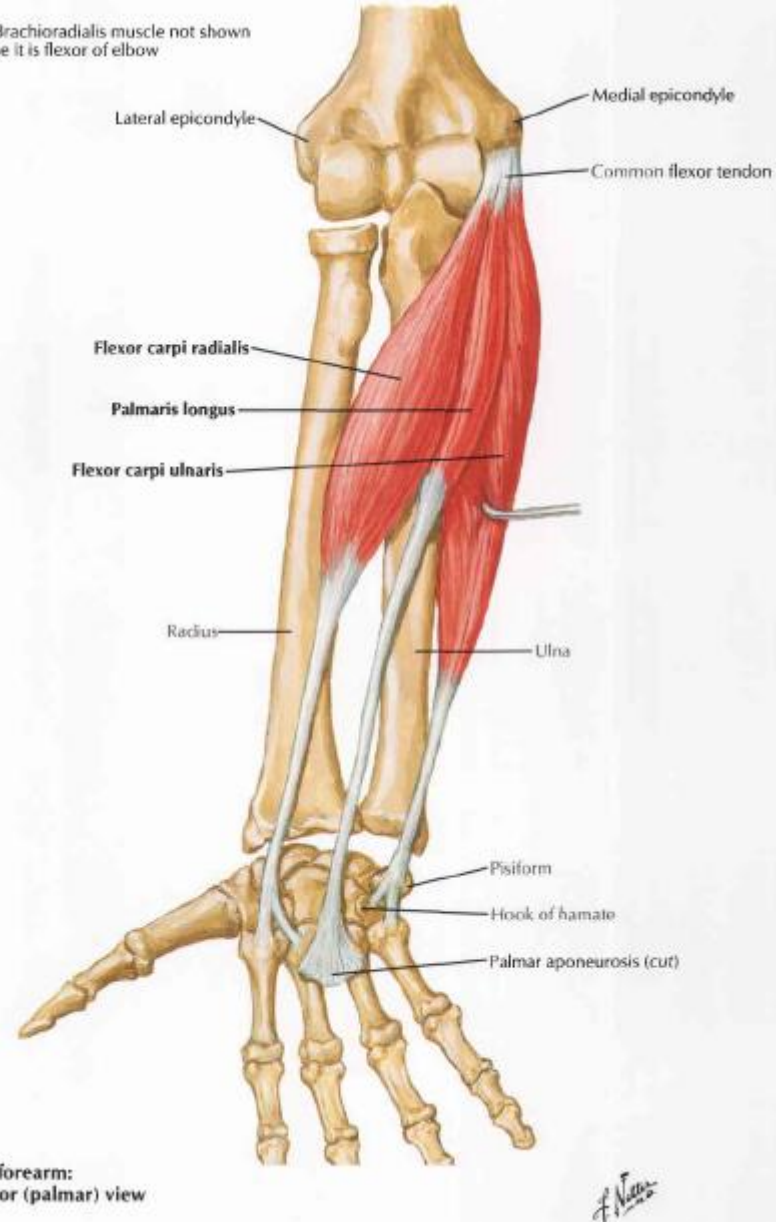
F. Netter

F. Netter





Note: Brachioradialis muscle not shown because it is flexor of elbow

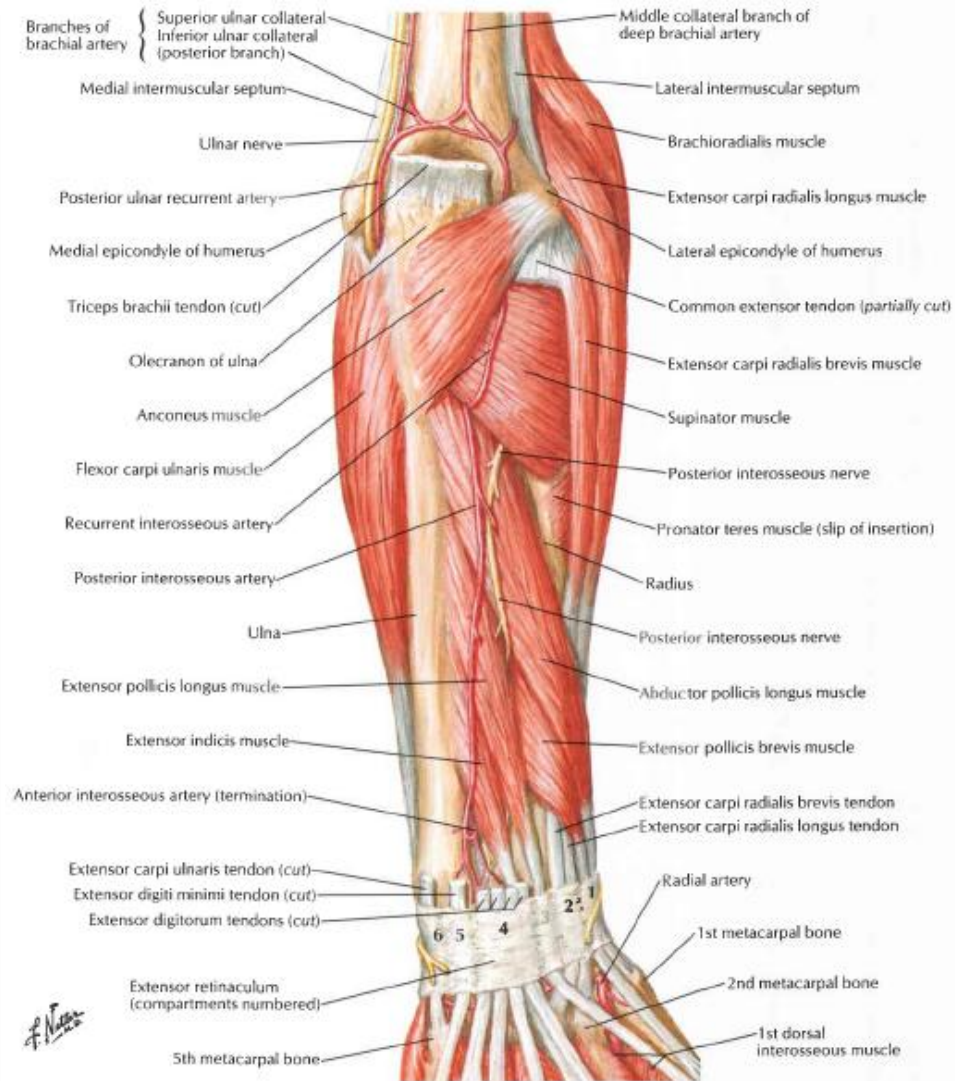
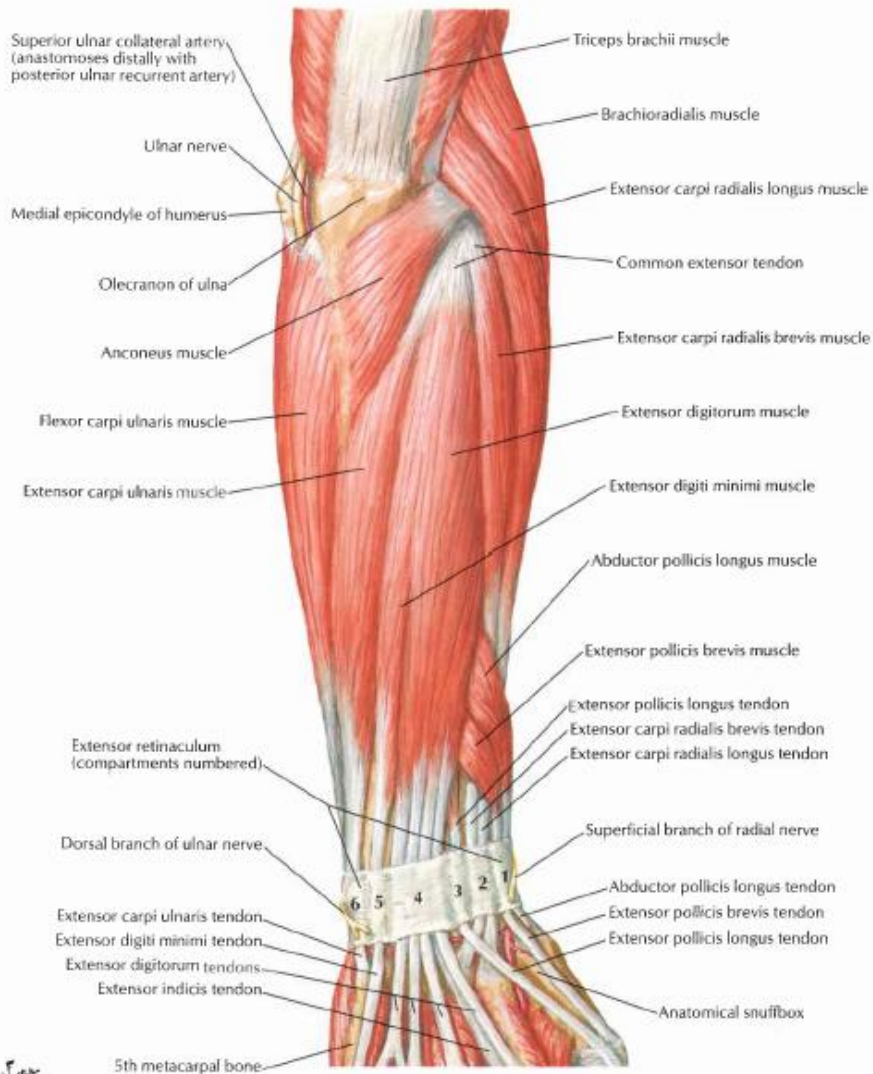


Otot Dorsal Lengan Bawah

Superficial		
1.	M. Extensor digitorum (communis)	N. Radialis (plexus brachialis, pars infraclavicularis)
2.	M. Extensor digiti minimi	
3.	M. Extensor carpi ulnaris	
Profunda		
1.	M. Supinator	N. Radialis (plexus brachialis, pars infraclavicularis)
2.	M. Extensor pollicis longus	
3.	M. Extensor pollicis brevis	
4.	M. Extensor indicis	
5.	M. Abductor pollicis longus	

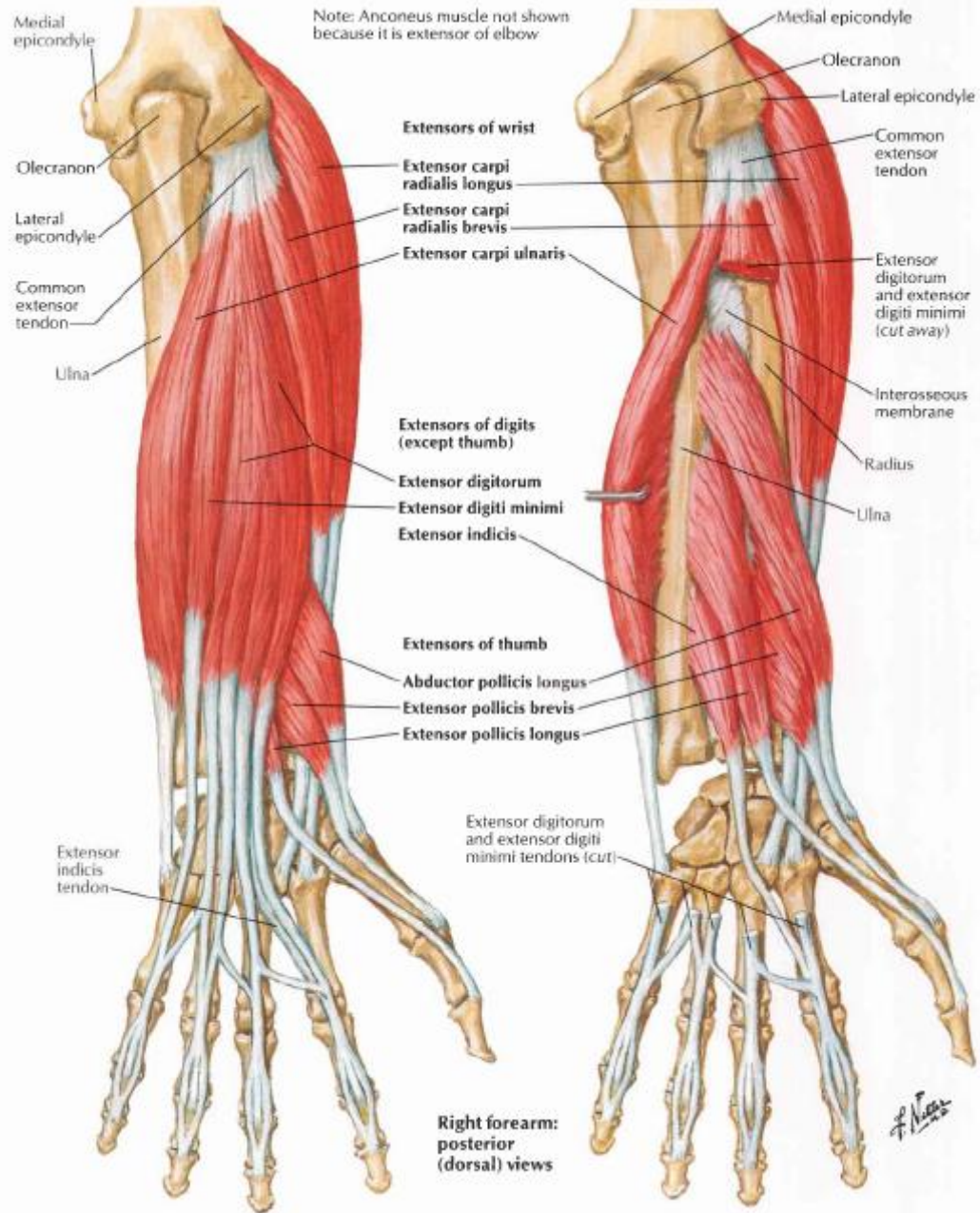
Otot Lateral Lengan Bawah

1.	M. Brachioradialis	N. Radialis (plexus brachialis, pars infraclavicularis)
2.	M. Ekstensor carpi radialis longus	
3.	M. Ekstensor carpi radialis brevis	



F. Netter

F. Netter

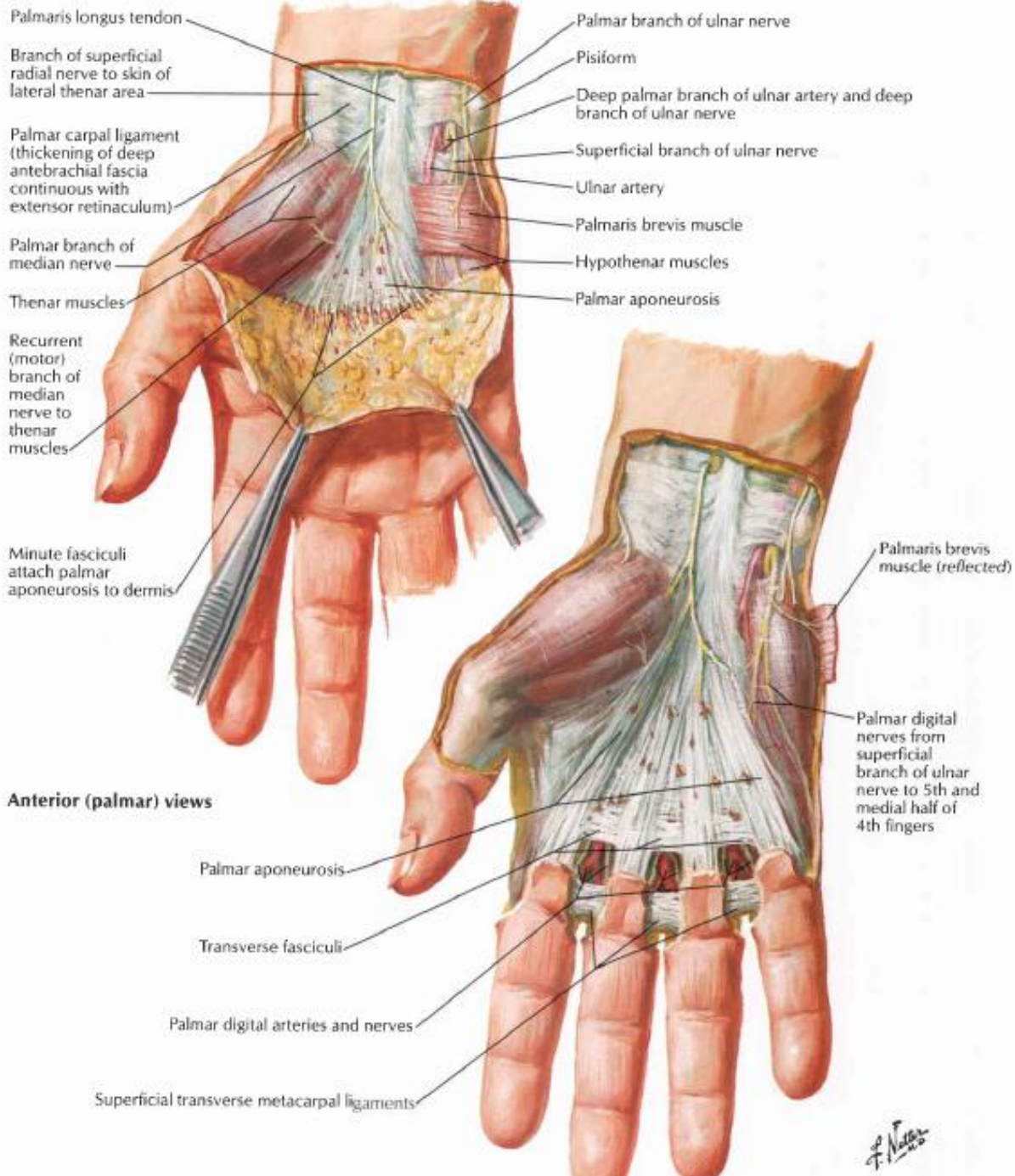


Otot Hypothenar

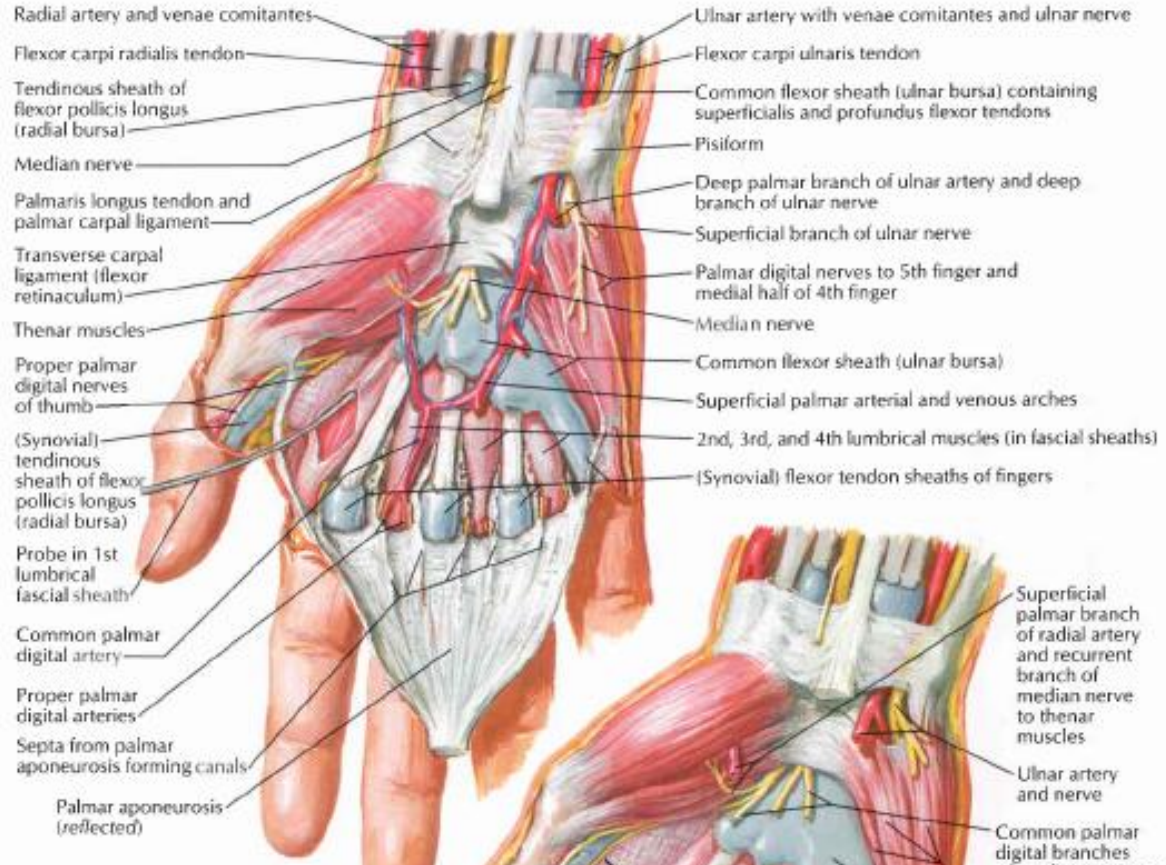
1.	M. Palmaris brevis	N. Ulnaris, R. Superficialis (plexus brachialis, pars infraclavicularis)
2.	M. Abductor digiti minimi	N. Ulnaris, R. profundus (plexus brachialis, pars infraclavicularis)
3.	M. Flexor digiti minimi brevis	
4.	M. Opponens digiti minimi	

Otot Thenar

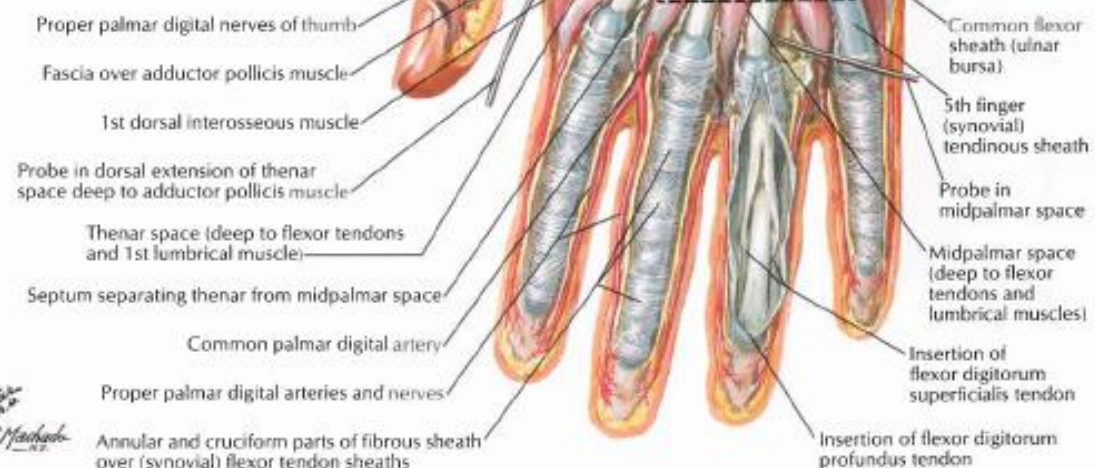
1.	M. Abductor pollicis brevis	N. Medianus (plexus brachialis, pars infraclavicularis)
2.	M. Flexor pollicis brevis	Caput superficial [N. Medianus]; caput profundum [N. Ulnaris], R. Profundus (plexus brachialis, pars infraclavicularis)
3.	M. Opponens pollicis	N. Medianus dan N. Ulnaris (plexus brachialis, pars infraclavicularis)
4.	M. Adductor pollicis	N. Ulnaris, R. Profundus (plexus brachialis, pars infraclavicularis)



F. Netter
2005



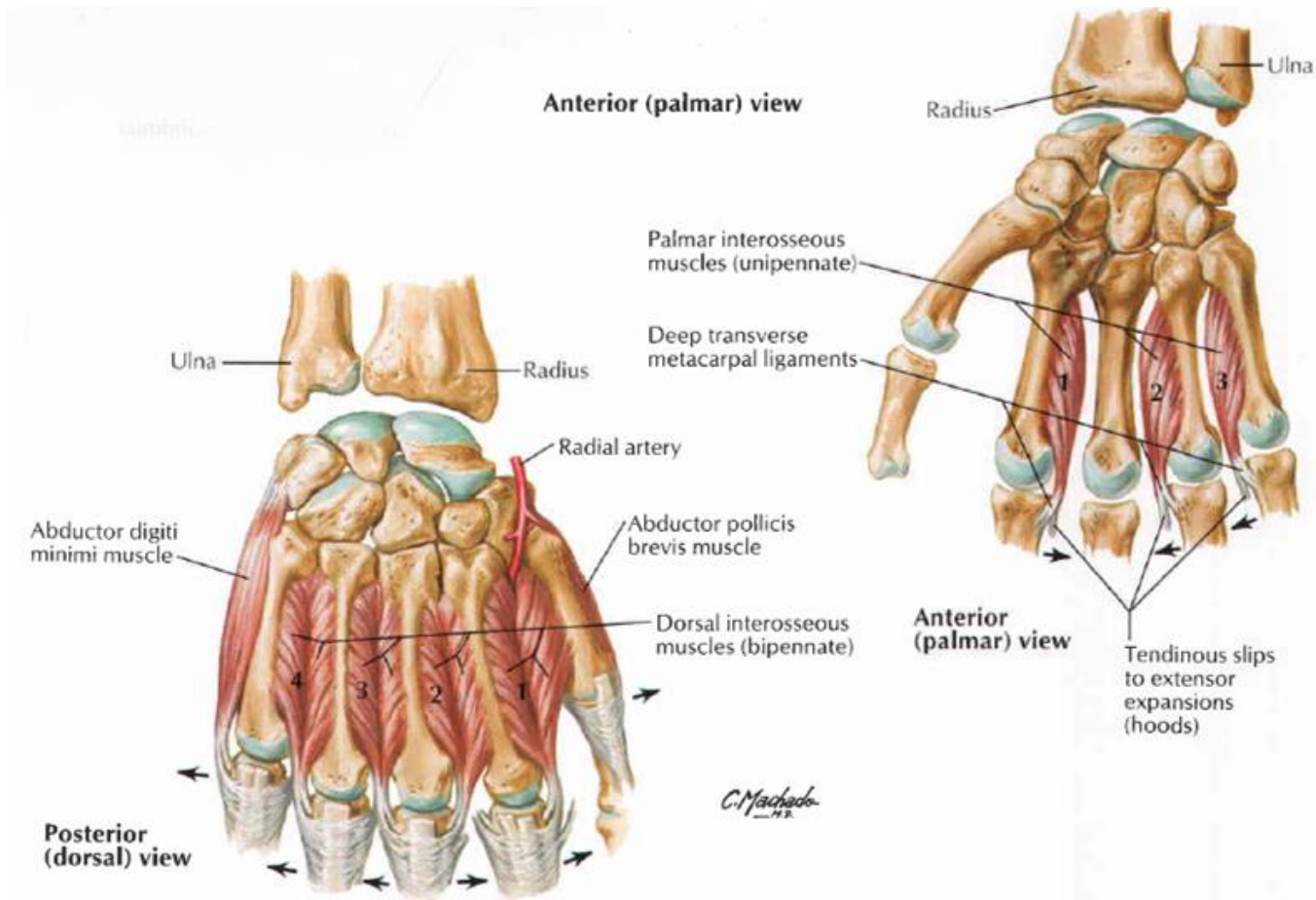
Anterior (palmar) views



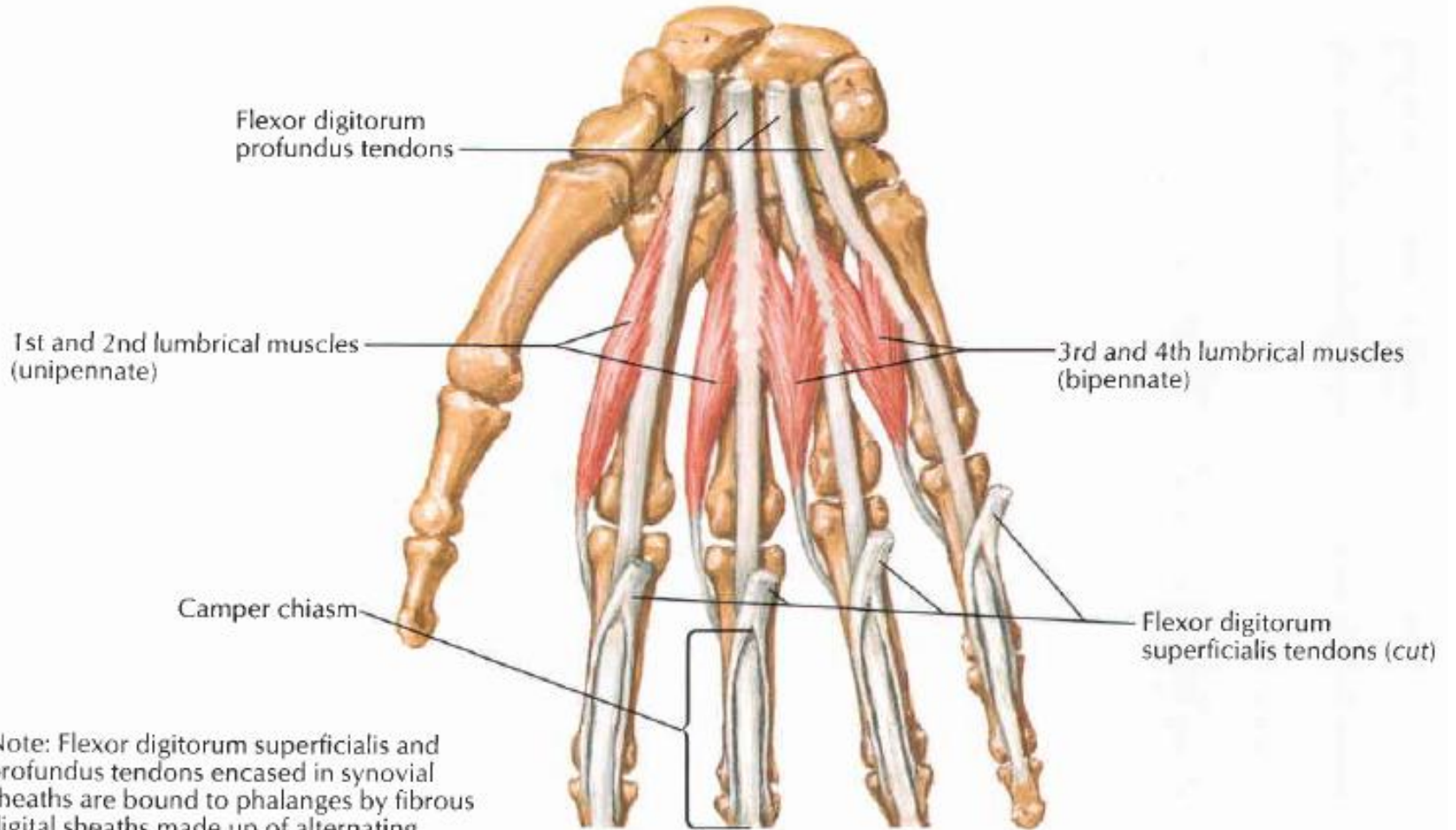
F. Netter M.D.
C. Machado

Otot Telapak Tangan

1.	Mm. Lumbricales I-IV	N. Medianus [I, II], N. Ulnaris [III-IV] (plexus brachialis, pars infraclavicularis)
2.	Mm. Interossei palmares I-III	N. Ulnaris (plexus brachialis, pars infraclavicularis)
3.	M. Interossei dorsalis I-IV	

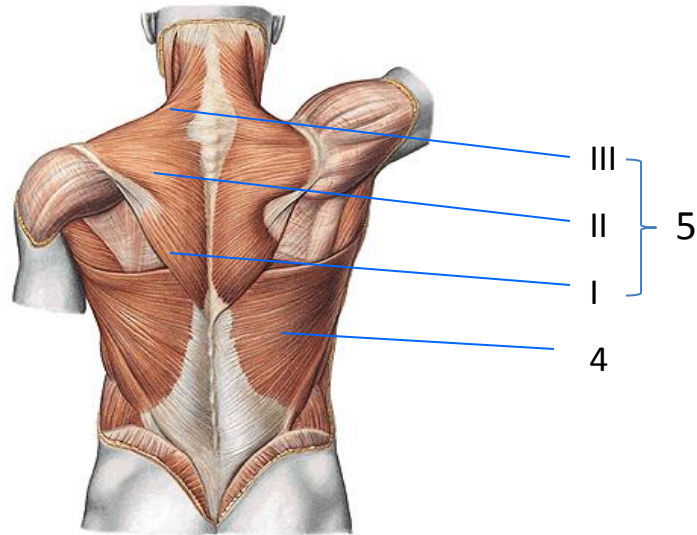


Lumbrical muscles: schema

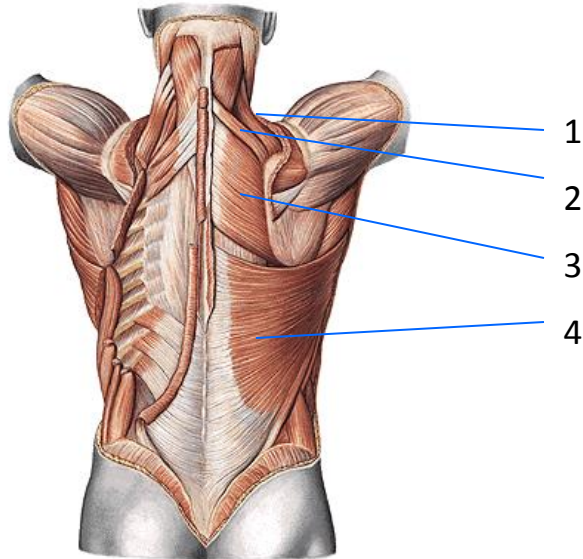


Note: Flexor digitorum superficialis and profundus tendons encased in synovial sheaths are bound to phalanges by fibrous digital sheaths made up of alternating strong annular (A) and weaker cruciform (C) parts (pulleys).

TOPOGRAFI OTOT EKSTREMITAS SUPERIOR



III }
II } 5
I }
4



1
2
3
4

1. M levator scapulae

2. M rhomboideus minor

3. M rhomboideus major

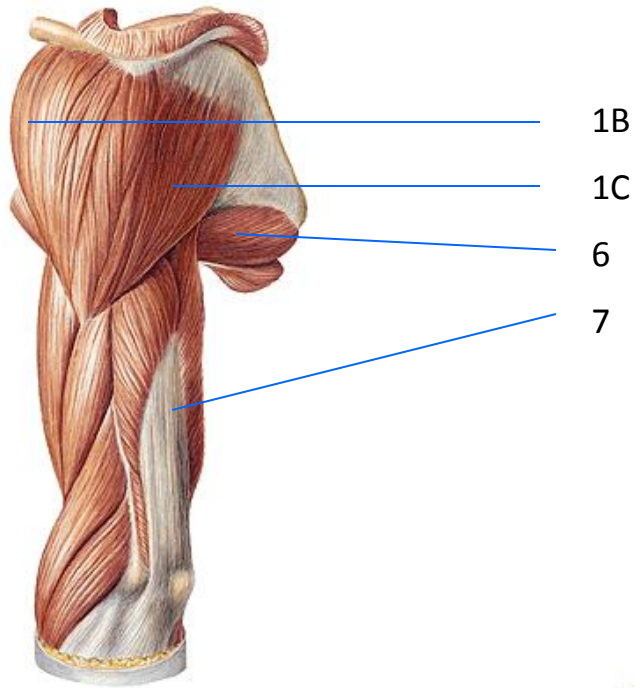
4. M latisimus dorsi

5. M trapezius

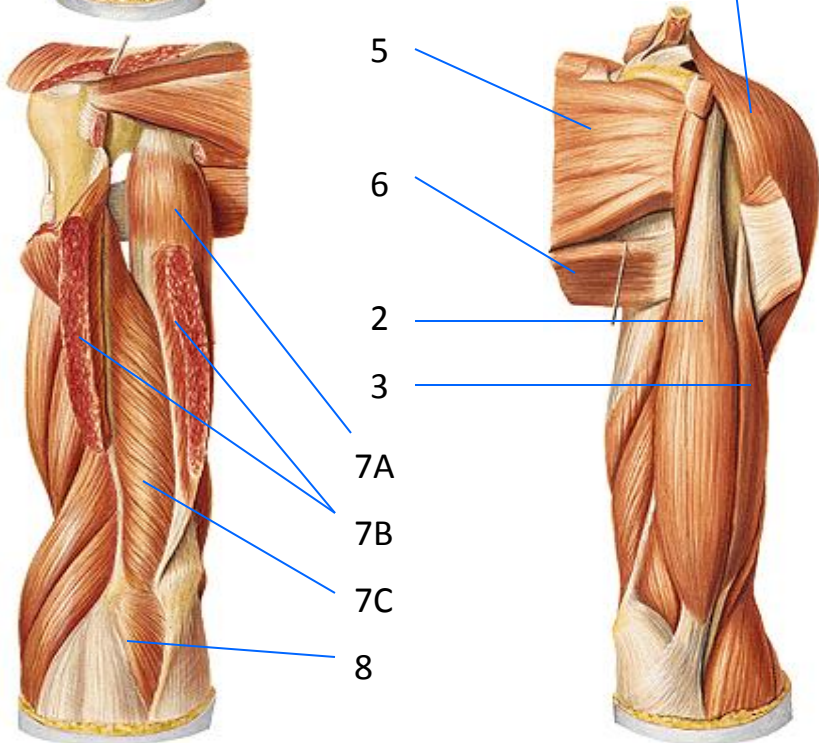
I. pars ascendens

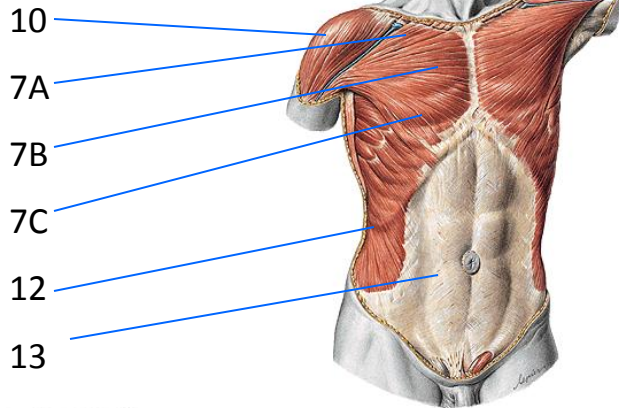
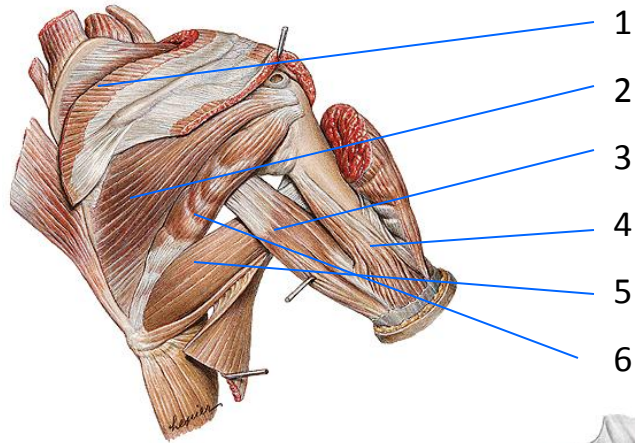
II. Pars transversa

III. Pars descendens

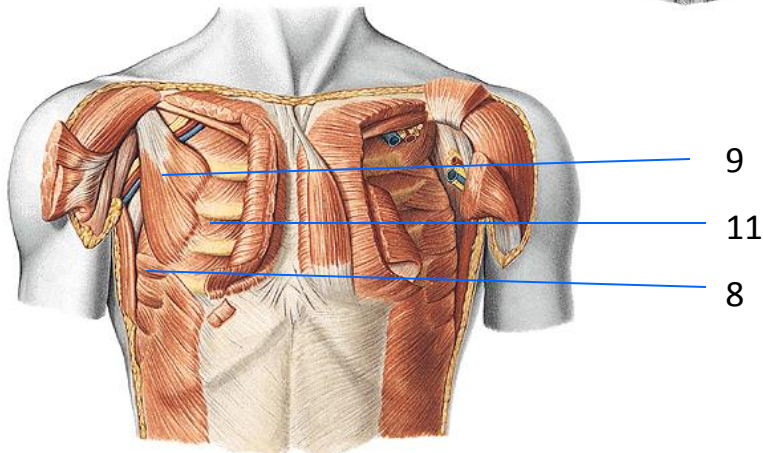


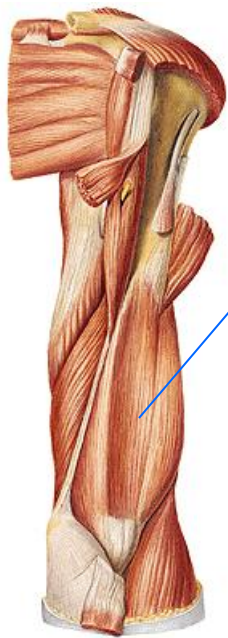
- | | |
|-------------------------------|-----------------------|
| 1. M deltoideus | 5. M subscapularis |
| A. Pars clavicularis | 6. M teres major |
| B. Pars acromialis | 7. M. triceps brachii |
| C. Pars spinalis | A. Cap longum |
| 2. M biceps brachii cap breve | B. Cap laterale |
| 3. M biceps brachii cap long. | C. Cap mediale |
| 4. M coracobrachialis | 8. M anconeus |



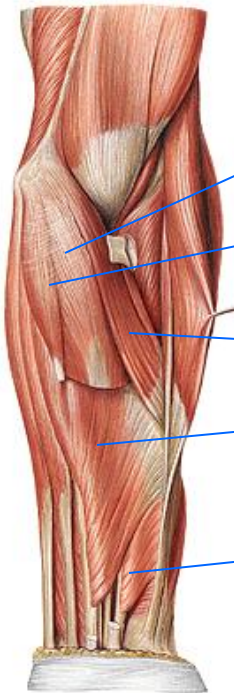
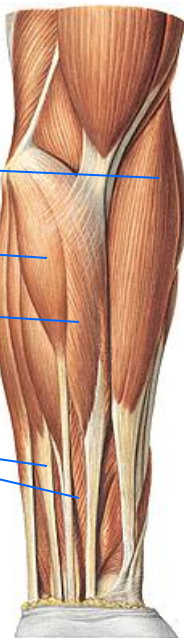


- | | |
|--------------------------|-------------------------|
| 1. M supraspinatus | 8. M serratus anterior |
| 2. M infraspinatus | 9. M pectoralis minor |
| 3. M triceps br cap long | 10. M deltoideus |
| 4. M triceps br cap lat | 11. M intercostalis |
| 5. M teres major | 12. m. obliquus ext abd |
| 6. M teres minor | 13. M rectus abdominis |
| 7. M pectoralis major | |
| A. Pars clavicularis | |
| B. Pars sternocostalis | |
| C. Pars abdominalis | |

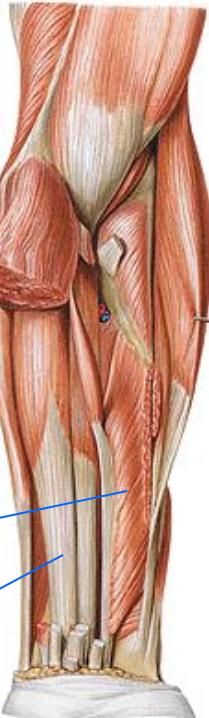



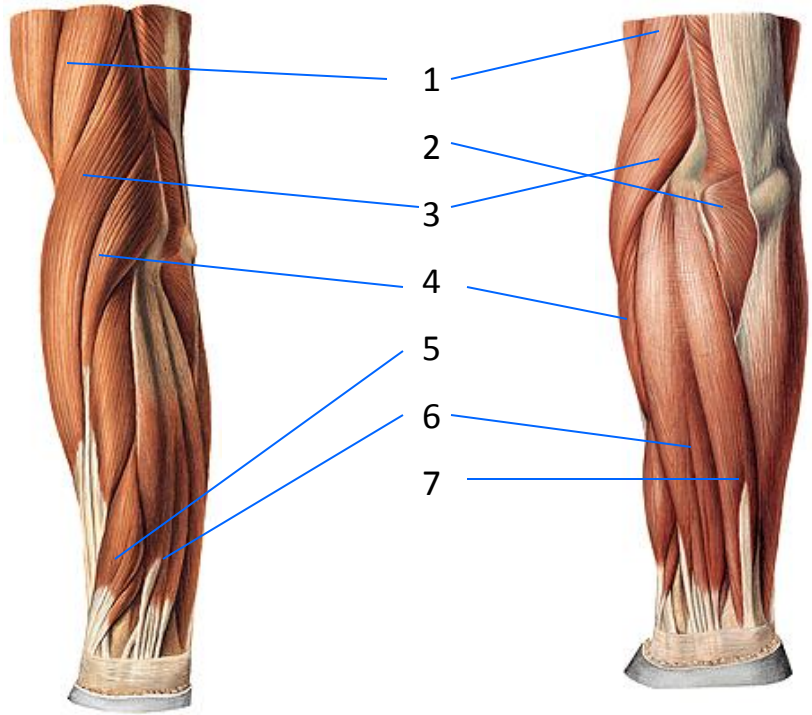
1
2
4
3
5
6



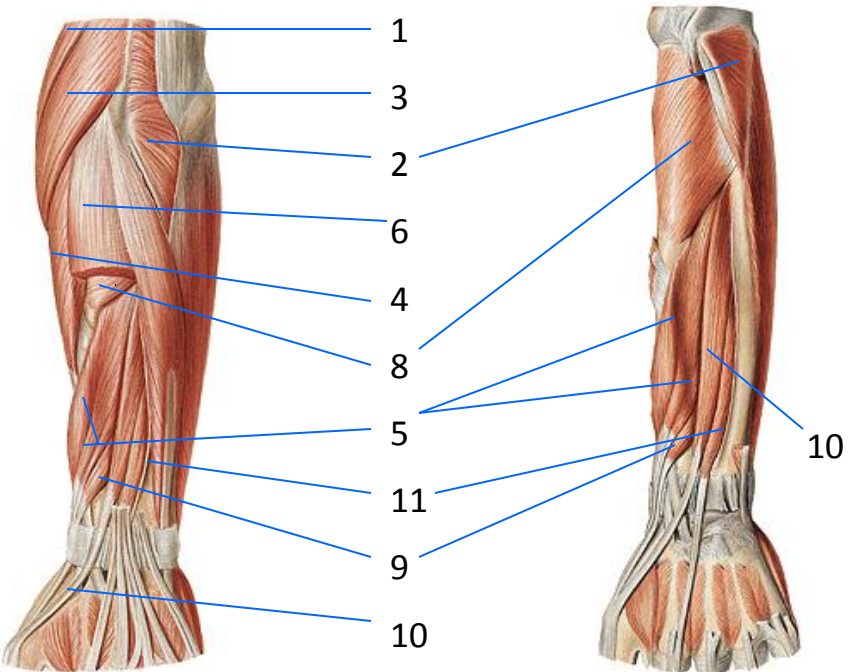
3
4
7
6
8
9



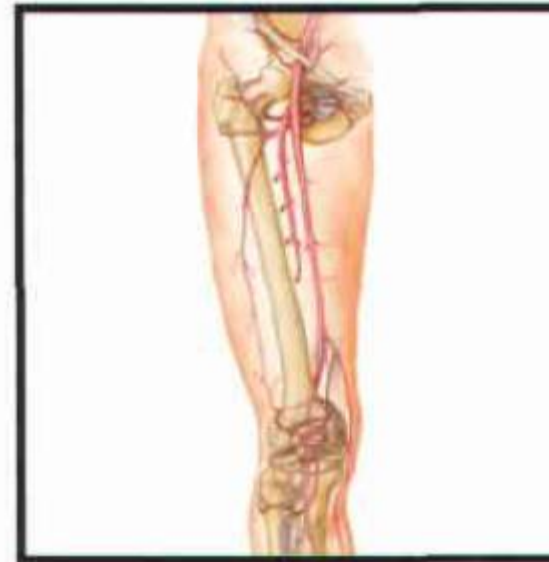
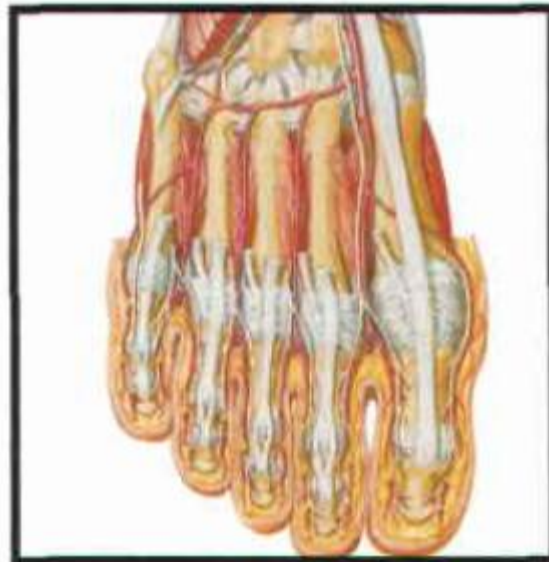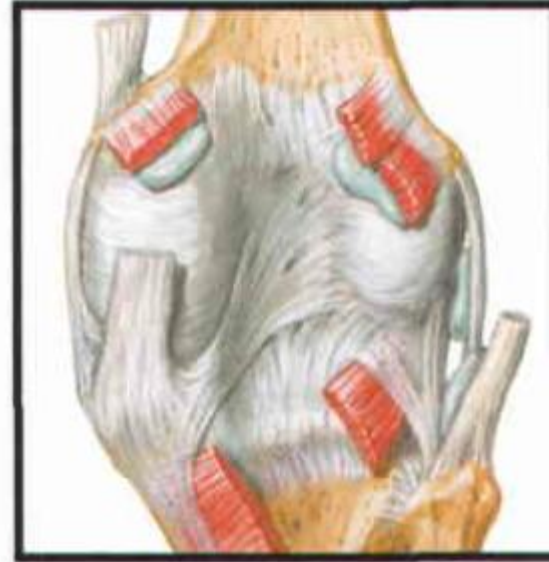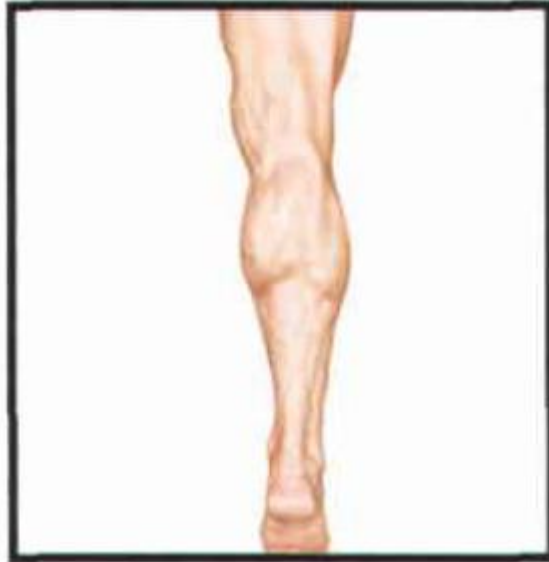
- | | |
|-----------------------------|------------------------------|
| 1. M brachialis | 6. M fleksor digitorum sup |
| 2. M brachiradialis | 7. M pronator teres |
| 3. M fleksor carpi radialis | 8. M fleksor pollicis longus |
| 4. M palmaris longus | 9. M fleksor digitorum |
| 5. M fleksor carpi ulnaris | |



- | | |
|------------------------------|----------------------------|
| 1. M brachioradialis | 7. M extensor carp ulnaris |
| 2. M anconeus | 8. M supinator |
| 3. M extensor carpi rad long | 9. M ext pollicis brevis |
| 4. M ext carp rad brevis | 10. M ext pollicis longus |
| 5. M abd pollicis longus | 11. M extensor indicis |
| 6. M extensor digitorum | |



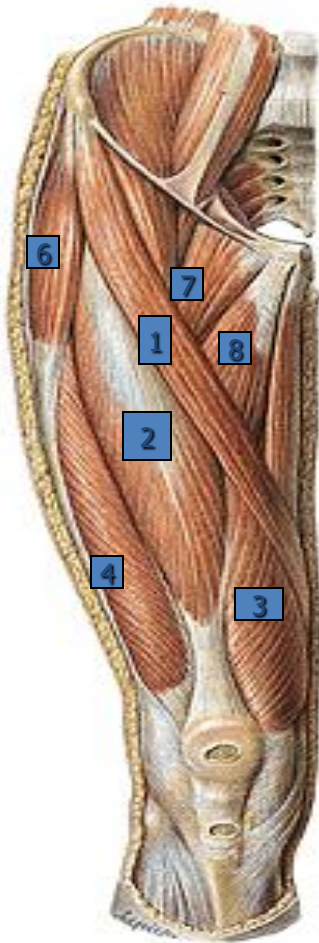
EKSTREMITAS INFERIOR



Otot Ventral Pangkal Paha		
1.	M. Iliacus	Rr. Musculares (plx. Lumbalis)
2.	M. Psoas major	
3.	M. Psoas minor	

Otot Ventral Paha		
1.	M. Quadriceps femoris	N. Femoralis (plx. Lumbalis)
	- M. Rectus femoris	
	- M. Vastus medialis	
	- M. Vastus lateralis	
	- M. Vastus intermedius	
	- M. Articularis genu	
2.	M. sartorius	N. Gluteus superior (plx. Lumbalis)
3.	M. Tensor fasciae latae	

Muscle of the Thigh and Hip



1. M. Sartorius:
2. M. Rectus femoris
3. M. Vastus medialis
4. M. Vastus lateralis
5. M. Vastus intermedius
2,3,4 dan 5 → m. Quadriceps femoris
6. M. Tensor fascia latae
7. M. Pectineus
8. M. Adduktor longus

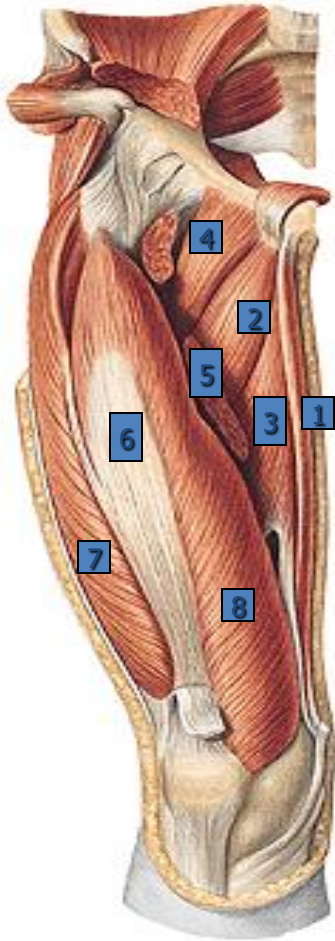
Otot Medial Paha Atas

1.	M. gracilis	N. Obturatorius (plx. Lumbalis)
2.	M. pectineus	
3.	M. Obturatorius externus	
4.	M. Adductor brevis	
5.	M. Adductor longus	
6.	M. Adductor magnus	N. Obturatorius (plx. Lumbalis) dan N. Ischiadicus (bagian tibial - plx. Sacralis)

Otot Dorsal Paha

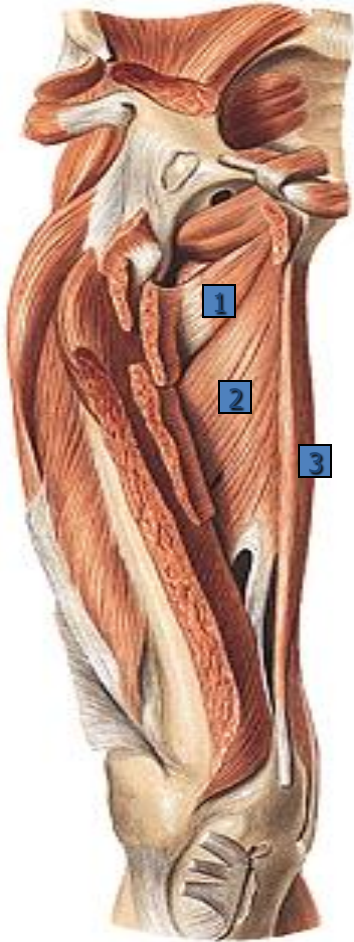
1.	M. Biceps femoris	Caput longum: N. Ischiadicus, bagian tibial (plx. Sacralis); caput breve: N. Ischiadicus, bagian fibula (plx. Sacralis)
2.	M. semitendinosus	N. Ischiadicus, bagian tibial (plx. Sacralis)
3.	M. semimembranosus	

Muscle of the Thigh (deep layer)



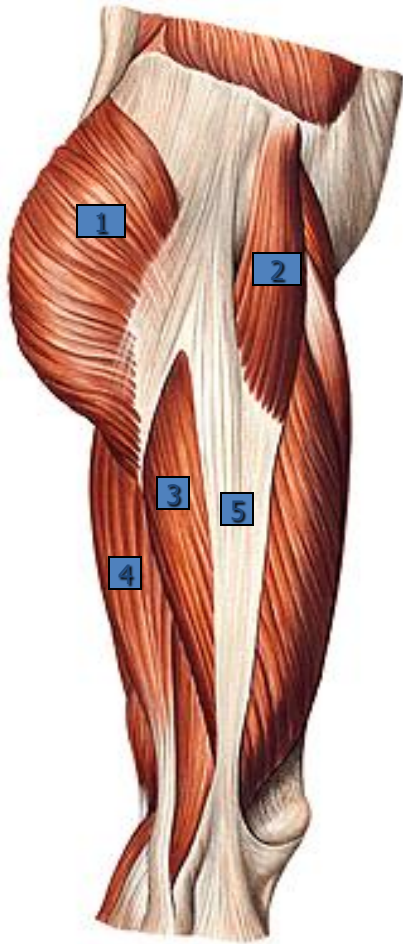
1. M. Gracilis
2. M. Adductor brevis
3. M. Adductor magnus
4. M. Pectineus
5. M. Adductor longus (potongan)
6. M. Vastus intermedius
7. M. Vastus lateralis
8. M. Vastus medialis

Muscle of the Thigh (deep layer)



1. M. Adduktor minimus
2. M. Adduktor magnus
3. M. Gracilis

Muscle of the Thigh (lateral view)

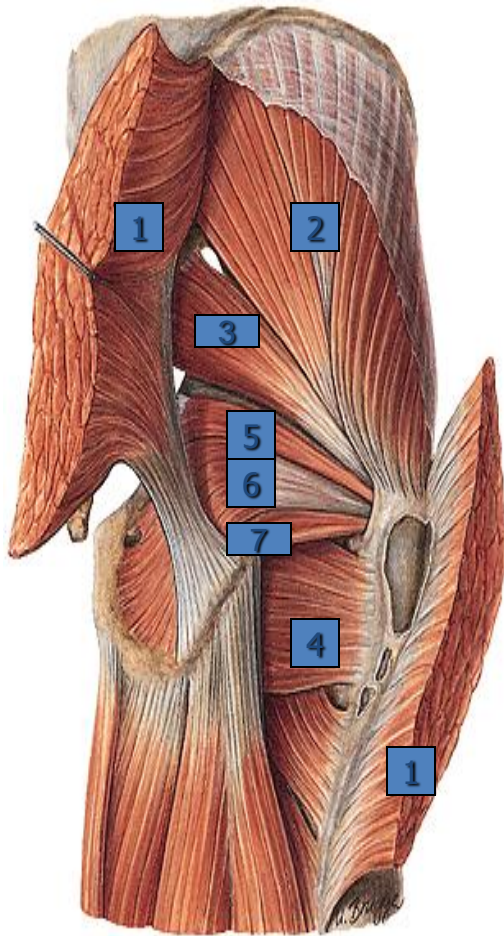


1. M. Gluteus maximus
2. M. Tensor fasciae latae
3. M. Vastus lateralis
4. M. Biceps femoris
5. Tractus iliotibialis

Otot Dorsal Pinggul

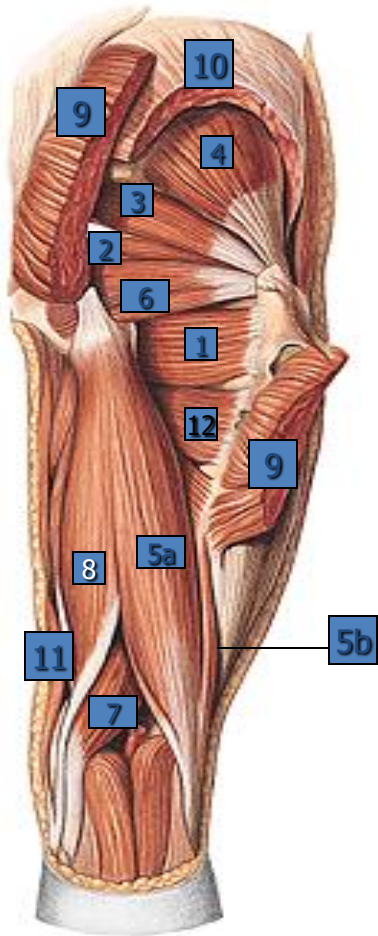
1.	M. Gluteus maximus	N. Gluteus inferior (plx. Sacralis)
2.	M. Gluteus medius	N. Gluteus superior (plx. Sacralis)
3.	M. Gluteus minimus	
4.	M. Piriformis	N. Ischiadicus dan/atau N. Musculi piriformis (plx. Sacralis)
5.	M. Obturatorius internus	N. Musculi obturatorii interni dan Rr. musculares (plx. Sacralis)
6.	M. Gemellus superior	
7.	M. Gemellus inferior	
8.	M. Quadratus femoris	N. Musculi quadrati femoris (plx. Sacralis)

Muscle of the Thigh (supervisial view)



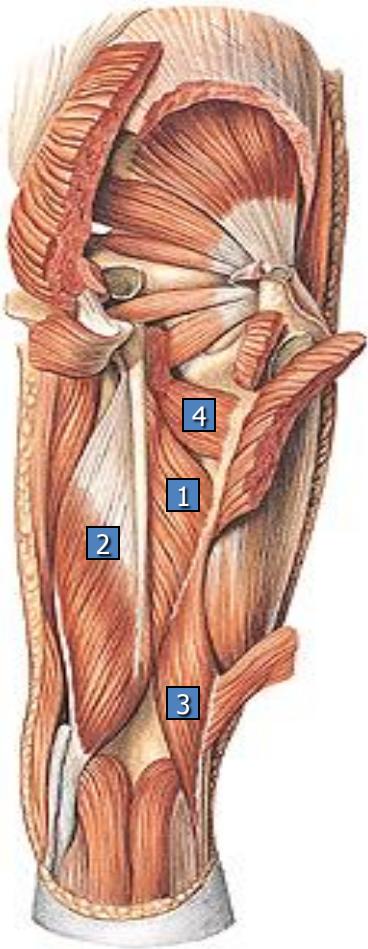
1. M. Gluteus maximus (potongan)
2. M. Gluteus medius
3. M. Piriformis
4. M. Quadratus femoris
5. M. Gemellus superior
6. M. Obturatorius internus
7. M. Gemellus inferior

Muscle of the Thigh (supervisual view)



1. M. Quadratus femoris
2. M. Obturator internus
3. M. Piriformis
4. M. Gluteus minimus
5. M. Biceps femoris
6. M. Gemellus superior
7. M. Semimembranosus
8. M. Semitendinosus
9. M. Gluteus maximus (potongan)
10. M. Gluteus medius (potongan)
11. M. Gracilis
12. M. Pectineus

Muscle of the Thigh (deep layer view)



1. M. Adductor magnus
2. M. Semimembranosus
3. M. Biceps femoris caput breve
4. M. Pectineus

Otot Betis

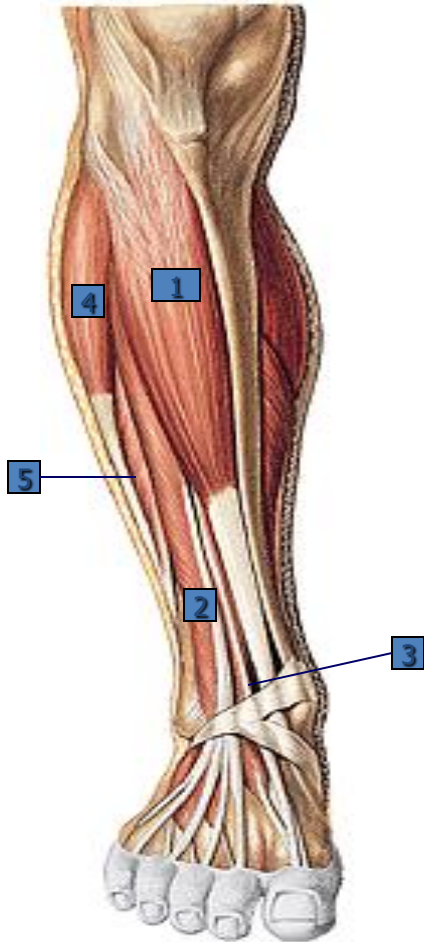
Ventral

1.	M. Tibialis anterior	N. Fibularis profundus (plx. Ischiadicus)
2.	M. Extensor hallucis longus	
3.	M. Extensor digitorum longus	
4.	M. Fibularis (peroneus) tertius	

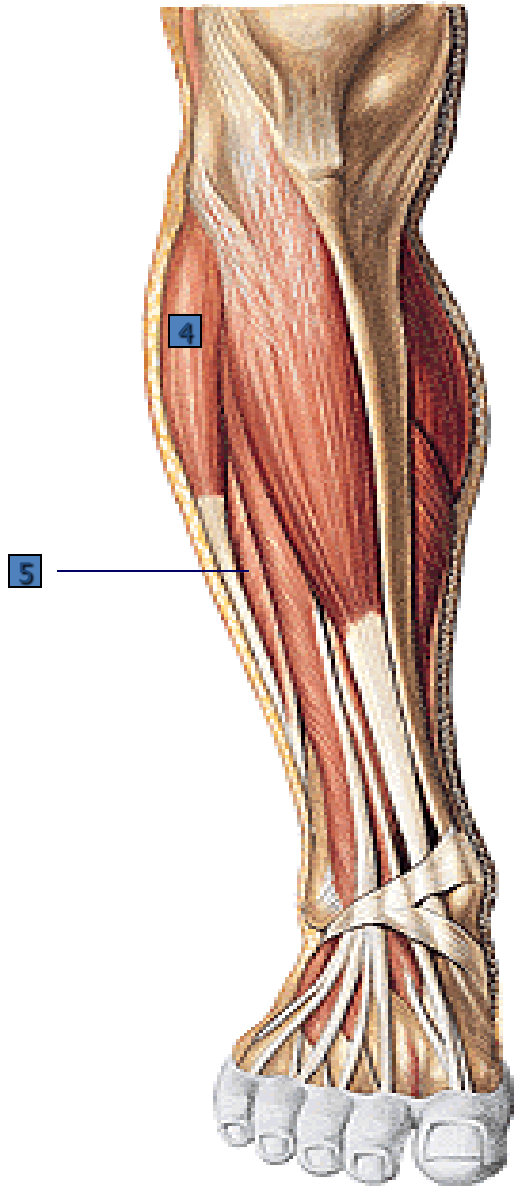
Lateral

1.	M. Fibularis (peroneus) longus	N. Fibularis superficialis (plx. Ischiadicus)
2.	M. Fibularis (peroneus) brevis	

Muscle of the crus and the foot



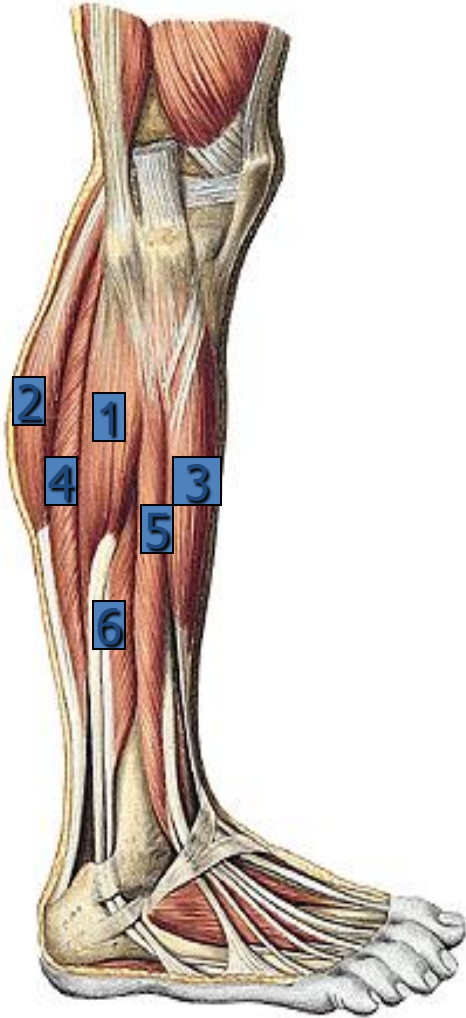
1. M. Tibialis anterior
2. M. Extensor digitorum longus
3. M. Extensor hallucis longus
4. M. Peroneus (fibularis) longus
5. M. Peroneus (fibularis) brevis



4. M. Peroneus (fibularis) longus

5. M. Peroneus (fibularis) brevis

Muscle of Region of the Knee and Crus



1. M. Peroneus (fibularis) longus
2. M. Gastrocnemius: (caput laterale)
3. M. Extensor hallucis longus
4. M. Soleus
5. M. Extensor digitorum longus
6. M. Peroneus (fibularis) brevis

Otot Dorsal Betis

Superficial

1. M. Triceps surae
 - M. gastrocnemius
 - M. soleus
 - M. plantaris

Profunda

1. M. popliteus
2. M. Tibialis posterior
3. M. Flexor digitorum longus
4. M. Flexor hallucis longus

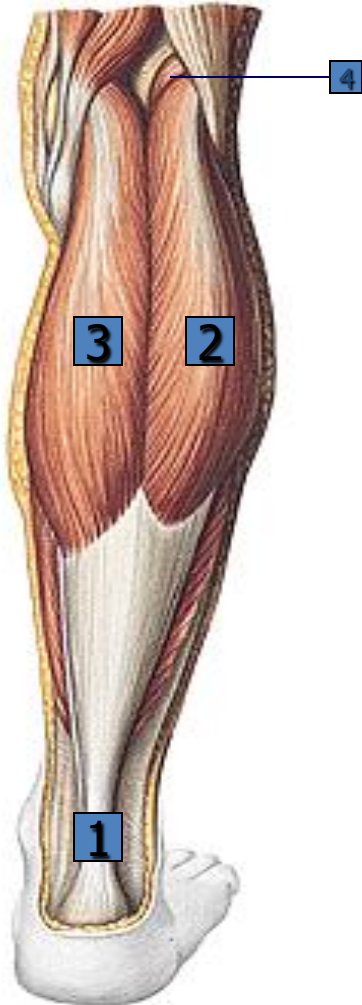
N. Tibialis (N. Ischiadicus)

Otot Dorsal Kaki

1. M. Extensor digitorum brevis
2. M. Extensor hallucis brevis

N. Fibularis profundus (N. Fibularis profundus)

Muscle of Crus



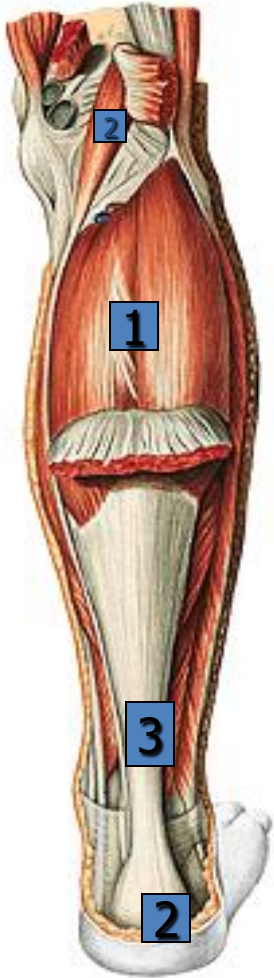1. Tendo achilles

2. M. Gastrocnemius caput laterale

3. M. Gastrocnemius caput mediale

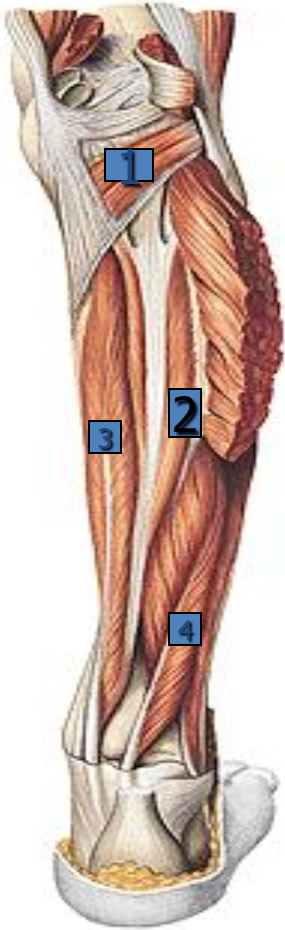
4. M. Plantaris

Muscle of Crus



1. m. soleus
2. Tuber calcaneus
3. Tendo archiles
4. m. plantaris

Muscle of Crus



1. M. Popliteus
2. M. Tibialis posterior
3. M. Flexor digitorum longus
4. M. Flexor hallucis longus

Otot Telapak Kaki Medial

1.	M. Abductor hallucis	N. Plantaris medialis (N. Tibialis)
2.	M. Adductor hallucis	
3.	M. Flexor hallucis brevis	Bagian medial: N. Plantaris medialis (N. Tibialis) Bagian lateral: N. Plantaris lateralis (N. Tibialis)

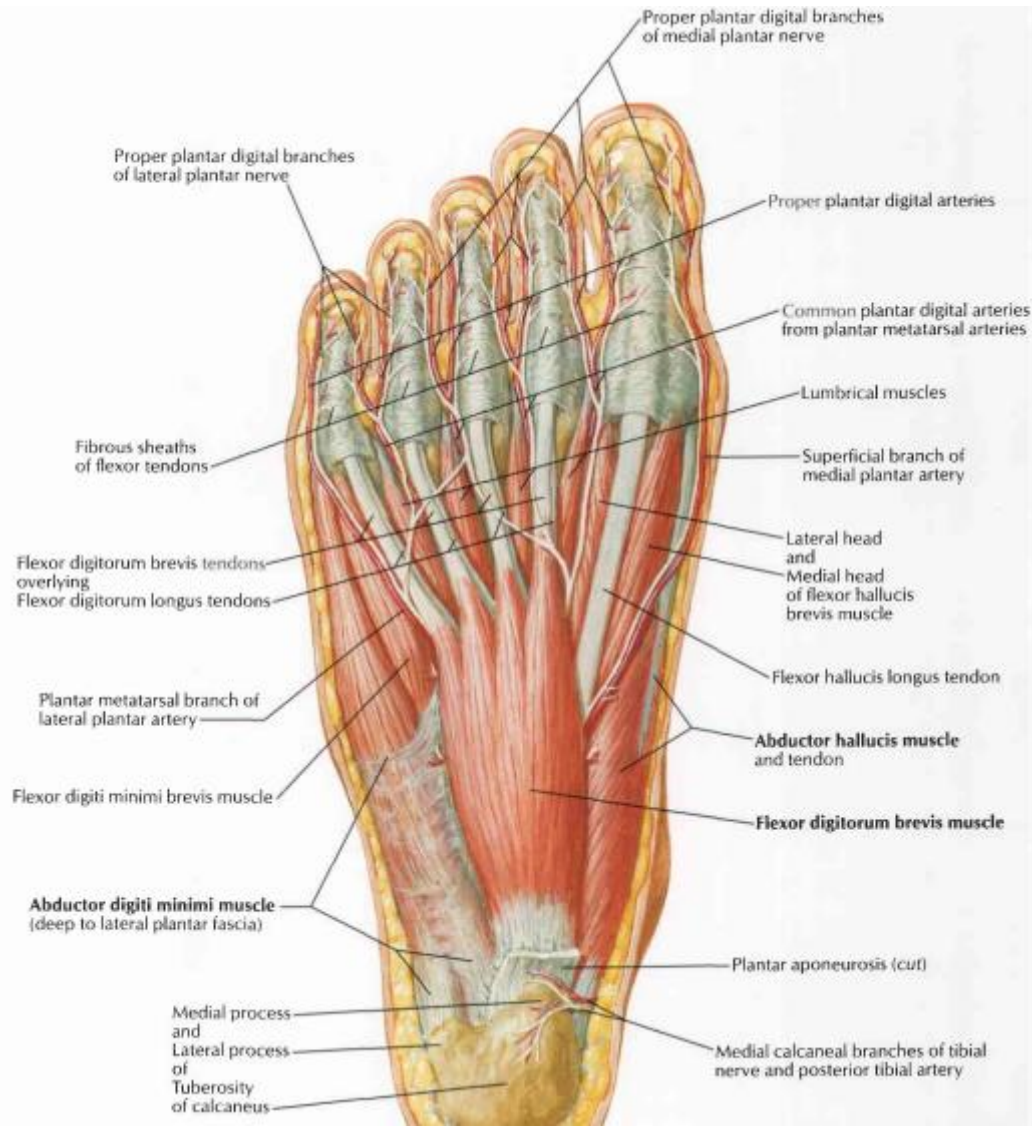Otot Telapak Kaki Intermedial

1.	M. Flexor digitorum brevis	N. Plantaris medialis (N. Tibialis)
2.	M. Lumbricales pedia I-IV	I: N. Plant. medialis, II-IV: N. Plant. lateralis (N. Tibialis)
3.	Mm. Quadratus plantae (acesorius)	N. Plantaris lateralis (N. Tibialis)
4.	Mm. Interossei plantares I-III	
5.	Mm. Interossei dorsales pedis I-IV	

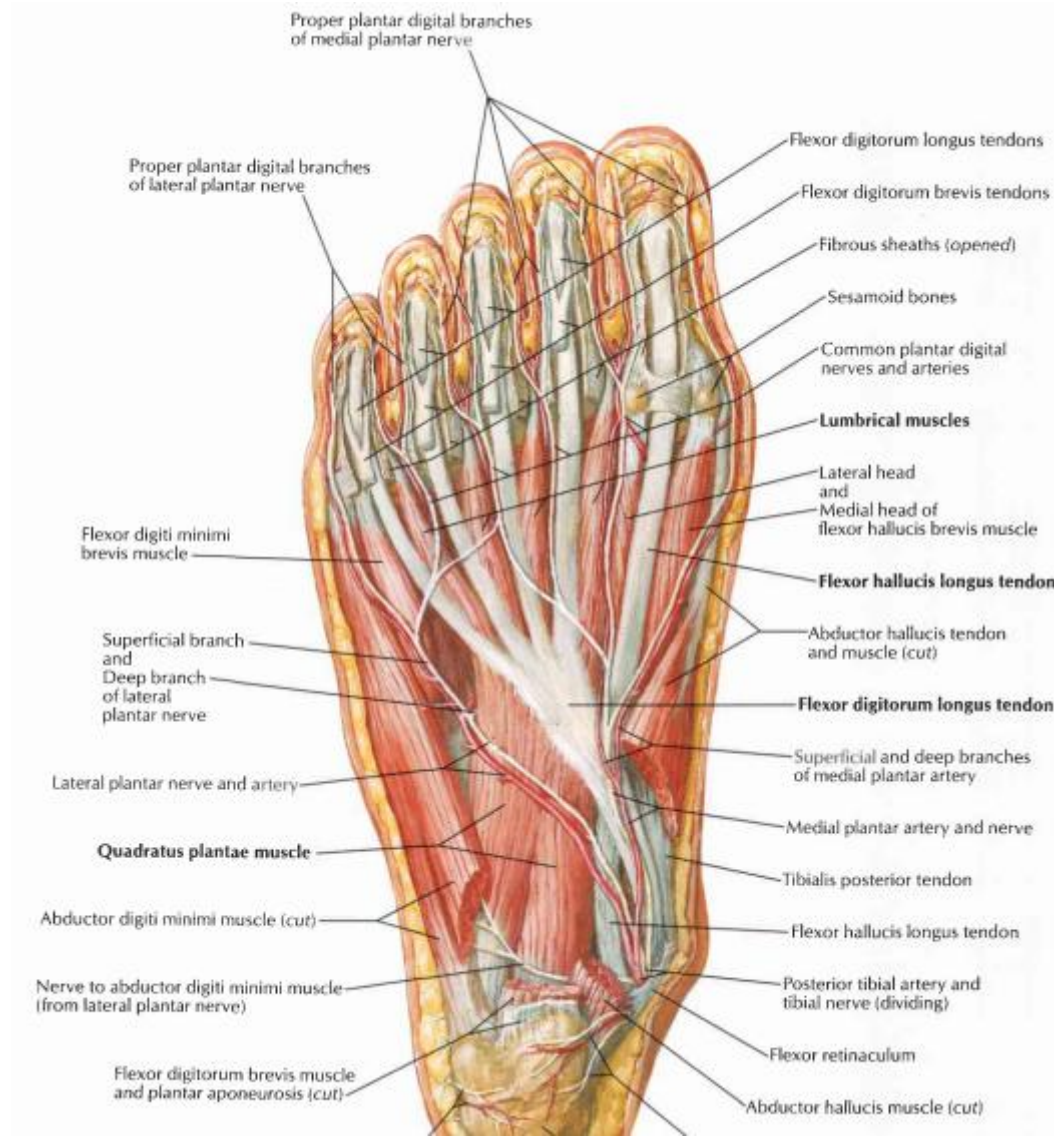
Otot Telapak Kaki Lateral

1.	M. Abductor digiti minimi	N. Plantaris lateralis (N. Tibialis)
2.	M. Flexor digiti minimi brevis	
3.	M. Opponens digiti minimi	

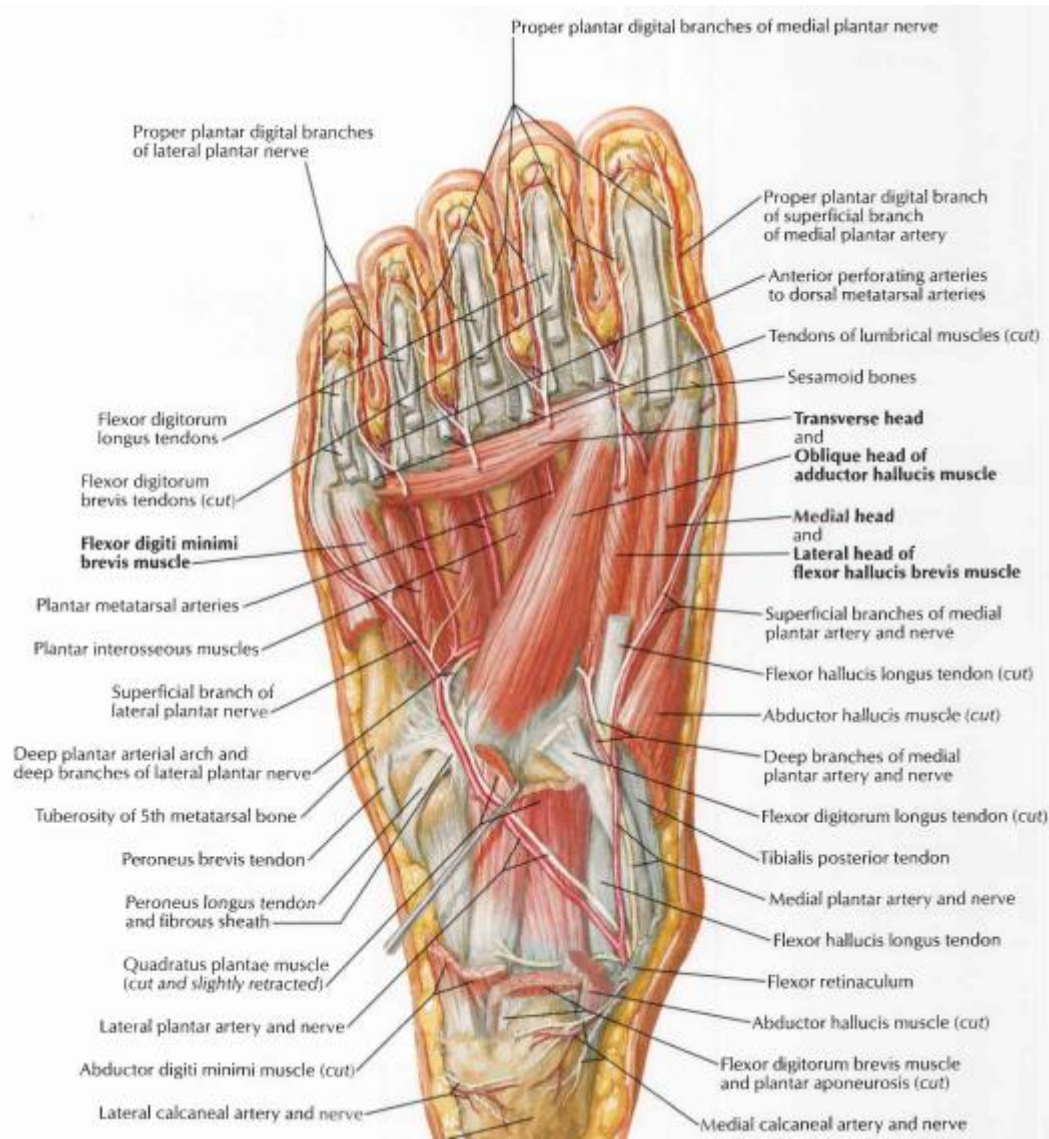
Otot Telapak Kaki (lapisan I)



Otot Telapak Kaki (lapisan II)



Otot Telapak Kaki (lapisan III)



TERIMA KASIH

